



# Impact of Colchicine on Histology of Testis in Rats

Rand Abdulateef Abdullah<sup>1\*</sup> , Hana Khaleel Ismail<sup>2</sup> , and AL-Haaik Ammar Ghanim<sup>3</sup>

<sup>1</sup>Department of Anatomy, College of Medicine, University of Mosul, Mosul, Iraq

<sup>2</sup>Department of Pathology, College of Veterinary Medicine, University of Mosul, Mosul, Iraq

<sup>3</sup>Department of Anatomy, College of Veterinary Medicine, University of Mosul, Mosul, Iraq

\*Corresponding author's E-mail: [rundabdulateef@uomosul.edu.iq](mailto:rundabdulateef@uomosul.edu.iq)

## ABSTRACT

Colchicine is a drug widely used for the management of many disorders, such as acute gout and Behçet's disease. It is also prescribed for the treatment of pericarditis, atrial fibrillation coronary artery diseases, and secondary amyloidosis. In case this drug is used at the early stages of coronavirus infection, its anti-inflammatory properties may reduce the severe inflammatory reactions related to a cytokine storm by affecting the inflammasome. The purpose of the present study was to determine the toxicity of Colchicine on testis in rats from different age groups for 10 days. A total of 27 male Wistar rats were divided into three groups. The rats in group I (control group) were administered distilled water by oral gavage. Group II consisted of young rats (5-6 months old) who orally received Colchicine 3 mg/kg body weight. Group III entailed rats of 14-16 months who were orally administered colchicine 3 mg/kg body weight. The testis of the treated groups was dissected and examined for histological changes and morphometrical analysis. The obtained results indicated that high doses of Colchicine (3 mg/kg body weight) could induce tissue damage to the testis, including degeneration and necrosis of both Sertoli and Leydig cells with irregular divisions of germinal epithelium, even when it was used for short periods (10 days). In the elderly treated rats, there were severe tissue damages, including degeneration and necrosis of germinal epithelium with irregular divisions of germ cells, necrosis of Sertoli and Leydig cells with sloughing of germinal epithelium toward the lumen of the tubule. Therefore, there is a need to conduct more studies to investigate the side effect of Colchicine as it is excessively used in the management of coronavirus.

**Keywords:** Colchicine, Histology, Morphometric trait, Rat, Testis

## INTRODUCTION

Colchicine (C<sub>22</sub>H<sub>25</sub>NO<sub>6</sub>) is an alkaloid extract originating from *Colchicum autumnale* seeds (Bertram et al., 2012). It is commonly prescribed for the management of acute attacks of gouty arthritis (Schlesinger et al., 2006), Behçet's syndrome (Yurdakul et al., 2001; Dasgeb et al., 2018), familial Mediterranean fever with associated amyloidosis (Hasbani et al., 2019). Furthermore, it is prescribed for the management of pericarditis (Schenone et al., 2018), atrial fibrillation (Siak et al., 2021), coronary artery diseases (Vaidya et al., 2019), and skin disorders (Saxena et al., 2019; Sardana et al., 2020).

It has antimitotic action by inducing the cessation of cellular mitosis in the metaphase of the cell cycle and disrupting the inflammatory pathway inducing its anti-inflammatory action (Leung et al., 2015). It is attached to tubulin for forming irreversible tubulin-colchicine complexes and induces GTPase enzymatic action to enhance the loss of the microtubule causing its depolymerization and cessation of its elongation (Bhattacharyya et al., 2008; Angelidis et al., 2018). In addition, it can arrest the meiotic divisions in murine (Liang et al., 1985). Colchicine is recently used for the treatment of covid 19 patients (Lopes et al., 2021; Scarsi et al., 2020) due to its anti-inflammatory action (Li et al., 2021; Kurek et al., 2021). It causes alterations in many inflammatory reactions as it prevents the aggregations of macrophages at the site of inflammation-reducing cytokine release and production of superoxide by neutrophils (Martínez et al., 2018; Kamel et al., 2021; Vitiello et al., 2022).

Oral Colchicine is quickly absorbed by the gastrointestinal system, and then, is metabolized and processed in the hepatic and intestinal system through cytochrome (P450), P-glycoprotein, and demethylated to major metabolites named demethylcolchicine (Mizutani et al., 2008). It is excreted primarily through the intestinal and biliary systems. Only about 10-20% were eliminated by the renal system (Niel and Scherrmann, 2006). The current study aimed to determine the damaging effect of Colchicine on the testis by comparing the young treated rats with elderly ones.

ORIGINAL ARTICLE  
pjt: S232245682200031-12  
Received: 09 July 2022  
Accepted: 02 September 2022

## MATERIALS AND METHODS

### Ethical Committee Approval

Ethical approval was sought and accepted from the medical research ethical committee of Mosul University, Mosul, Iraq (UOM/COM/MREC/21-22(11)).

### Drug

The drug was obtained from Cipla Medpro, India, with the brand name Colchicine (1 mg).

### Experimental animals

A total of 27 male Wistar rats with a weight mean of 200 g were purchased from the experimental animal section in the Veterinary College/University of Mosul, Iraq. The rats were randomly divided into three groups with three replicates for each group. Group I was assigned as the control group, group II included young rats within the age range of 5-6 months, and group III entailed rats aged 14-16 months. Animals were housed in plastic cages (three per cage) in standard humidity and at room temperature maintained at 25°C. A controlled 12-hour light-dark cycle was maintained and they were given the diet *ad libitum* and normal tap water. Animals fed a balanced diet which was produced by the research council of the Veterinary College of Mosul University, Iraq.

### Dosage treatment

Group I (control group) received distilled water orally while groups II and III were administered Colchicine 3 mg/kg body weight daily for 10 days which was double therapeutic dose. All groups received the medicine by oral plastic gavage (15g/78 mm).

### Histology

The treated animals were sacrificed by diethyl ether 2 days after the last dose of Colchicine (day 12 of the experiment) was administered. The testis was excised and fixed with 10% neutral buffered formalin. Specimens were dehydrated by alcohol, cleared by clearing agent xylene, and blocks of paraffin wax were made. Then, paraffin sections were obtained and cut into 5-micrometer thickness. Finally, sections were stained with hematoxylin and eosin and examined under a light microscope (Olympus, Germany) in Al-Mahmood Laboratory for Histopathological Consulting, Mosul, Iraq.

### Histomorphometric approaches

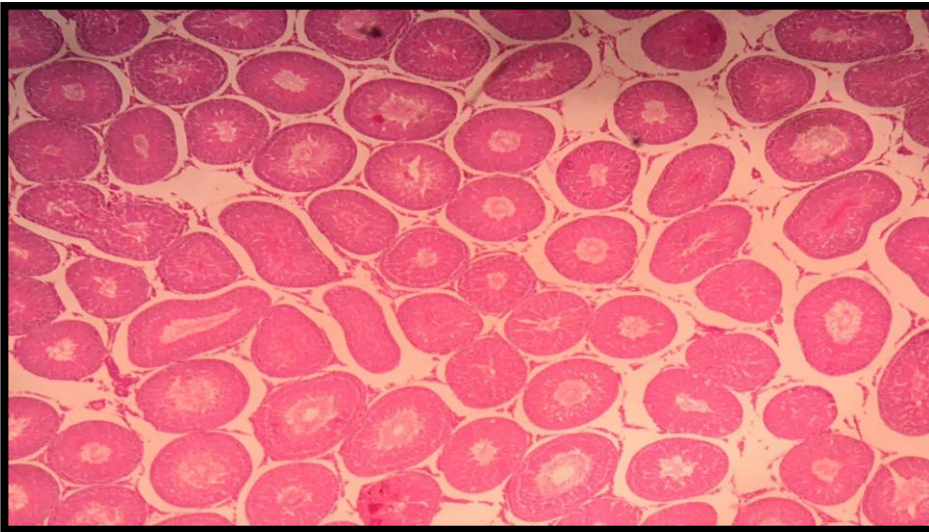
The investigated parameters in the current study included the diameter of the seminiferous tubule ( $\mu\text{m}$ ), thickness of the germinal layer ( $\mu\text{m}$ ), and perimeter of the seminiferous tubule ( $\mu\text{m}$ ). The number of Sertoli cell/tubule and number of Leydig cell/tubule were measured using 40x magnification of the microscope. A specialized digital camera (OMAX 18 MP, China) with USB 3.0 was used for morphometric estimation.

### Statistical analysis

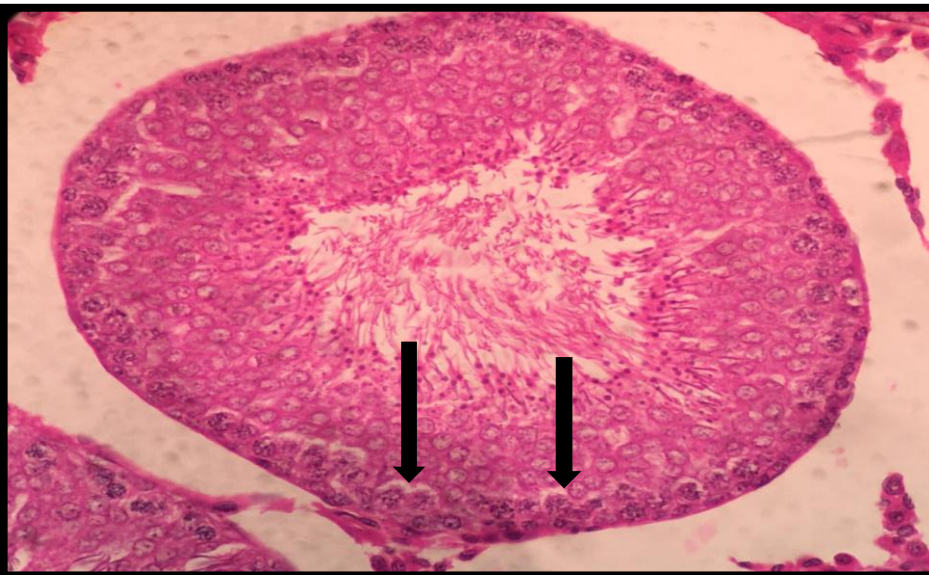
The morphometrical study was estimated by Sigma plot V12.0 / SYSTAT software. Parameters were determined as mean with standard error and evaluated by ANOVA test with significance at  $p < 0.05$ . Duncan's test was used to assess differences among the mean of groups (Kirkwood, 1988).

## RESULTS

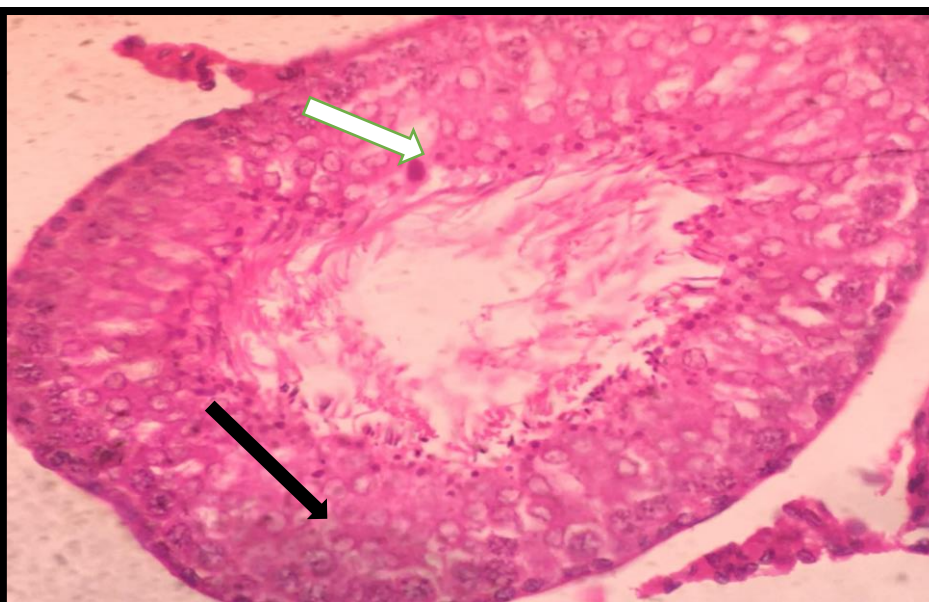
The tissue sections of the testis of group I showed normal histological features, including organized shape and size of seminiferous tubules, regular division, and maturation of spermatogonia cells. Normal germ cell proliferation and mature sperms were shown in the lumen of the tubules (Figure 1). The microscopic examination of histological sections of the testis of group II showed degeneration and necrosis of Sertoli cells (Figure 2). The findings indicated the irregular division of germinal epithelium with vacuolar degeneration of spermatid cells (Figure 3). There was interstitial edema between the seminiferous tubules with degeneration and necrosis of Leydig cells (Figure 4). As can be seen in Figure 5, there were vacuolar multinucleated giant cells and seminiferous tubules were free from sperms containing only cellular debris. The microscopic examination of tissue testis of group III showed more severe histopathological changes than group I, as it was characterized by degeneration and necrosis of germinal epithelium with severe vacuolation of spermatogonia cells (Figure 6). Irregular division of germ cells lining the tubules with necrosis of Sertoli cells and deformed, abnormal spermatocytes and spermatids were noticed. The lumen of seminiferous tubules was obstructed by cellular debris (Figure 7). Degeneration and necrosis of Leydig cells with interstitial edema and dilatation of seminiferous tubule lumen occurred due to the degenerative process (Figure 8). There was damage to the basement membrane of the tubules with sloughing of germinal epithelium toward the lumen of the tubule (Figure 9).



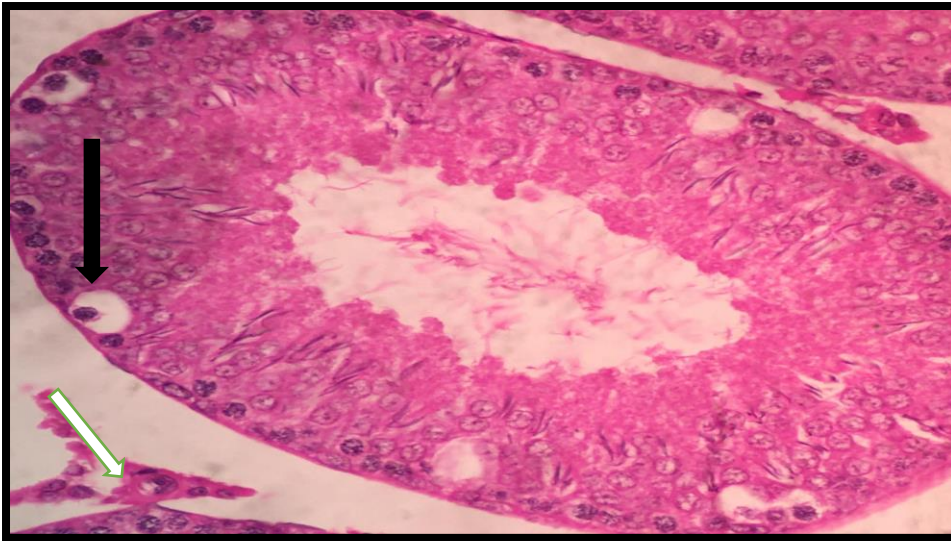
**Figure 1.** Normal architecture of testis in young rats (5-6 months old) with normal looking seminiferous tubules (H&E, 100X)



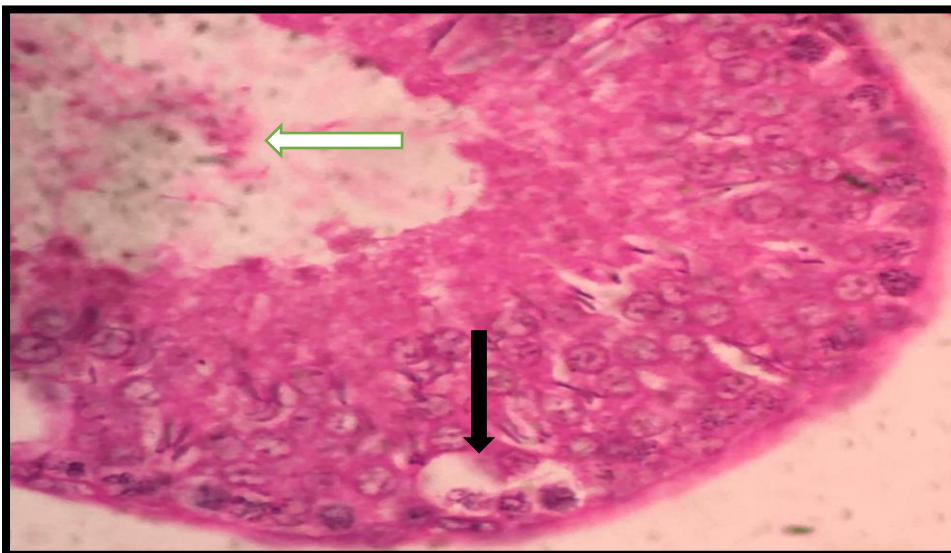
**Figure 2.** Degeneration and necrosis of sertoli cells in the young age treated rats (5-6 months old) with Colchicine (Black arrows, H&E stain, 400X)



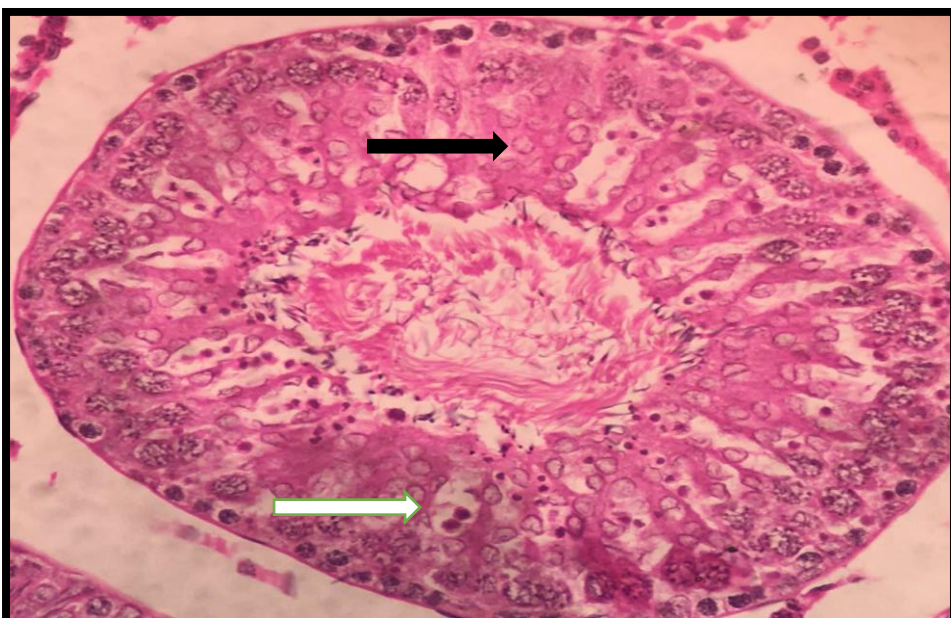
**Figure 3.** Irregular divisions of germinal epithelium (black arrow) in a young age rat (5-6 months old) treated with Colchicine. Vacuolar degeneration of spermatid cells (White arrow, H&E stain, 400X)



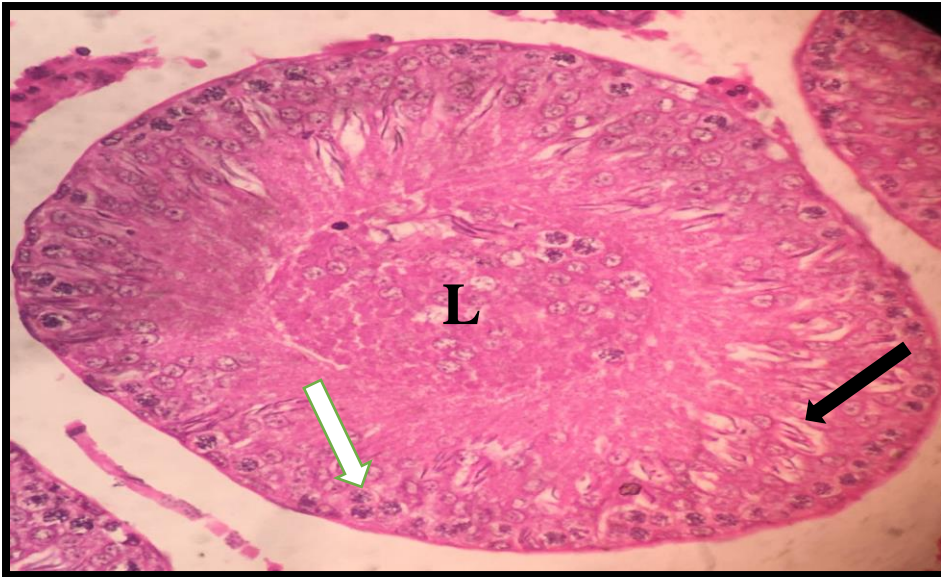
**Figure 4.** Vacuolar degeneration of spermatid cells (black arrow) in a young age rat (5-6 months old) treated with Colchicine. Degeneration of Leydig cells (White arrow, H&E stain, 400X)



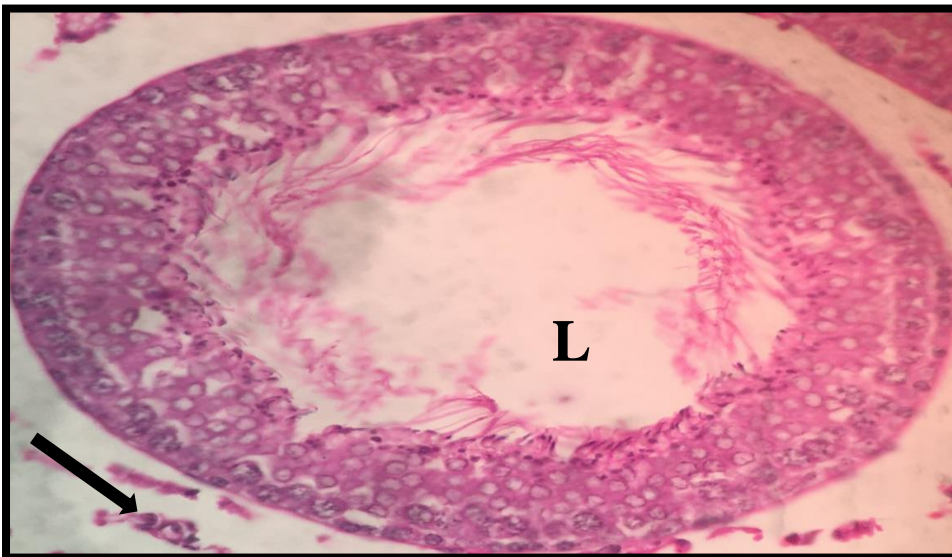
**Figure 5.** Vacuolar multinucleated giant cells (black arrow) in a young age rat (5-6 months old) treated with Colchicine. Cellular debris in the lumen without sperms (White arrow, H&E stain, 400X).



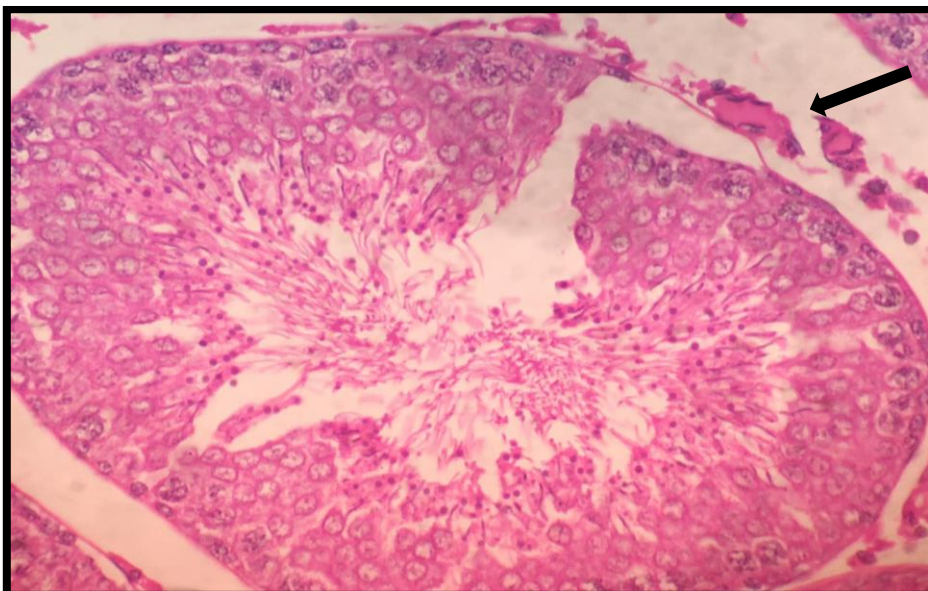
**Figure 6.** Degeneration and necrosis of germinal epithelium (black arrow) in old rats (14-16months old) treated with Colchicine. Severe vacuolation of spermatogonia cells (White arrow, H&E stain, 400X).



**Figure 7.** Irregular divisions and abnormal shape of germ cells (black arrow) with necrosis of Sertoli cells (white arrow) in an old rat (14-16 months old) treated with Colchicine. Obstructed lumen by cellular debris (L, H&E stain, 400X).



**Figure 8.** Degeneration and necrosis of Leydig cells (black arrow) in an old rat (14-16 months old) treated with Colchicine. Dilated lumen with debris (L, H&E stain, 400X)



**Figure 9.** Damage of the basement membrane of the seminiferous tubules in an old rat (14-16 months old) treated with Colchicine (black arrow, H&E, 400X)

## Morphometric analysis

### Seminiferous tubules diameter

The diameter of the seminiferous tubules/  $\mu\text{m}$  of group I (control group) was  $247.9 \pm 4.7$ . The diameter of young age-treated rats (group II) was  $224.92 \pm 5.3$ . However, in the old age-treated rats (group III), the diameter was  $184.84 \pm 4.2$  (Table 1, Graph 1).

### Germinal epithelium thickness

The germinal epithelium thickness /  $\mu\text{m}$  of group I (control group) was  $(80.94 \pm 2.5)$ . The thickness was  $78.234 \pm 1.9$  in group II, it was  $62.34 \pm 1.6$  in group III (Table 1 and Graph 1).

### Seminiferous tubules perimeter

The seminiferous tubules perimeter/ $\mu\text{m}$  was reported as  $40347.56 \pm 986.4$ ,  $39901.42 \pm 734.9$ , and  $34718.3 \pm 917.3$  in groups I, II, and III, respectively (Table 2 and Graph 2).

### Sertoli cell

The number of Sertoli cell/tubules in groups I, II, and III was measured as  $11.2 \pm 0.8$ ,  $11.6 \pm 0.5$ , and  $9.8 \pm 0.3$ , respectively (Table 3 and Graph 3).

### Leydig cell

Regarding the number of Leydig cells/40x field, group I indicated  $10.2 \pm 0.5$ , while this number was  $8.2 \pm 0.7$  and  $5.2 \pm 0.3$  in groups II and III, respectively (Table 3 and Graph 3).

**Table 1.** Diameter of seminiferous tubule and the thickness of the germinal epithelial layer in rats with different age ranges treated with Colchicine

Groups	Treatment	Control	T1	T2
Seminiferous tubules diameter ( $\mu\text{m}$ )		$247.9 \pm 4.7^a$	$224.92 \pm 5.3^a$	$184.84 \pm 4.2^b$
The germinal epithelium thickness ( $\mu\text{m}$ )		$80.94 \pm 2.5^a$	$78.234 \pm 1.9^a$	$62.34 \pm 1.6^b$

Different superscript letters in the same row explain a significant statistical difference at  $p < 0.05$ . T1: Young rats (5-6 months old) were administered Colchicine 3 mg/kg body weight, T2: Old rats (14-16 months old) were administered Colchicine 3 mg/kg body weight

**Table 2.** Seminiferous tubule perimeter in rats with different age ranges treated with Colchicine

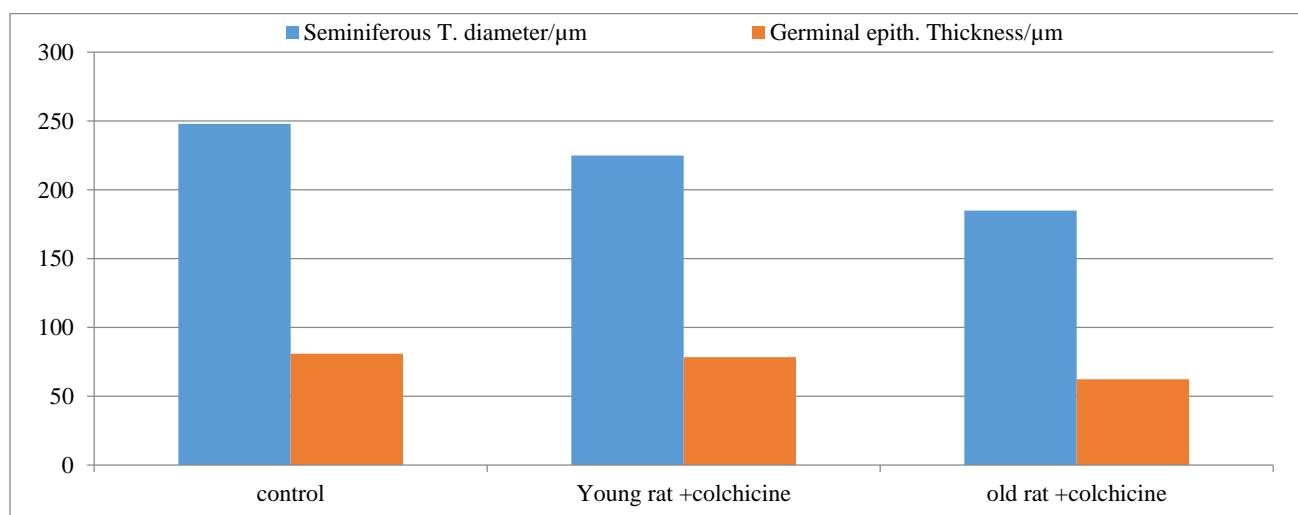
Groups	Treatment	Control	T1	T2
Seminiferous tubules perimeter/ $\mu\text{m}$		$40347.56 \pm 986.4^a$	$39901.42 \pm 734.9^{ab}$	$34718.3 \pm 917.3^b$

Different superscript letters in the same row explain a significant statistical difference at  $p < 0.05$ . T1: Young rats (5-6 months old) were administered Colchicine 3 mg/kg body weight, T2: Old rats (14-16 months old) were administered Colchicine 3 mg/kg body weight

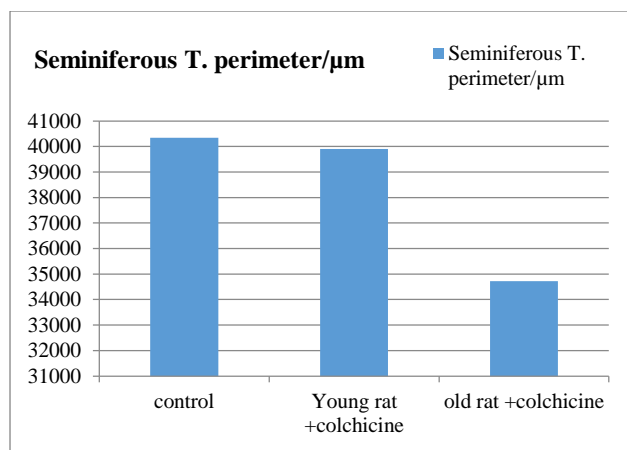
**Table 3.** Sertoli cell and Leydig cell in rats with different age ranges treated with Colchicine

Groups	Treatment	Control	T1	T2
Sertoli cell No./tubule		$11.2 \pm 0.8^a$	$11.6 \pm 0.5^a$	$9.8 \pm 0.3^b$
Leydig cell No./40x field		$10.2 \pm 0.5^a$	$8.2 \pm 0.7^a$	$5.2 \pm 0.3^b$

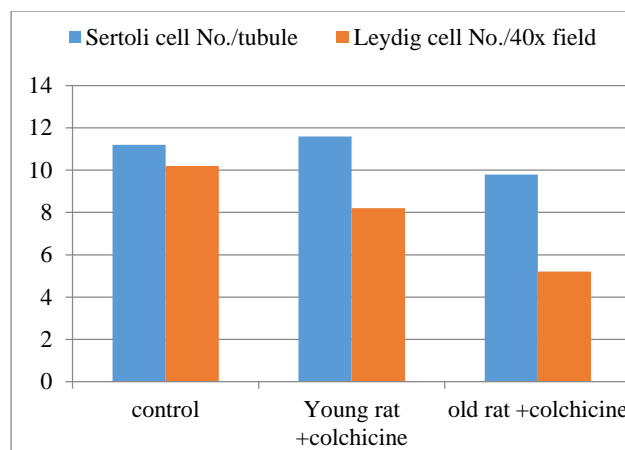
Different superscript letters in the same row explain a significant statistical difference at  $p < 0.05$ . T1: Young rats (5-6 months old) were administered Colchicine 3 mg/kg body weight, T2: Old rats (14-16 months old) were administered Colchicine 3 mg/kg body weight



**Graph 1.** Diameter of seminiferous tubule and the thickness of the germinal epithelial layer in rats with different age ranges treated with Colchicine



**Graph 2.** Perimeter of Seminiferous tubules in rats with different age ranges treated with Colchicine



**Graph 3.** Sertoli cell and Leydig cell in rats with different age ranges treated with Colchicine

## DISCUSSION

Colchicine has a narrow therapeutic index, meaning that it is a safe drug as long as it is used within the therapeutic dose but toxic in higher doses (Maxwell et al., 2001). It is widely used in the management of many disorders, such as like gout, but nowadays, it is used in the treatment of coronavirus patients as it has an anti-inflammatory action that reduces respiratory damage (Gómez et al., 2021).

Considering the obtained results of the current study, young rats in Group II showed some pathological changes, such as degeneration and necrosis of Sertoli cells, and irregular divisions of germinal epithelium vacuolar multinucleated giant cells. The lumen of the seminiferous tubules was free from sperms.

Unlike other groups, group III (the old age-treated rats) demonstrated more severe pathological changes, including degeneration and necrosis of the germinal epithelium. Moreover, there were irregular divisions with the abnormal shape of spermatocytes and spermatids with necrosis of Sertoli and Leydig cells. The lumen of seminiferous tubules was obstructed by cellular debris. Damage to the basement membrane of the tubules with sloughing of the germinal epithelium was also detected.

Concerning Morphometric analysis, all the parameters of group III showed a significant decrease. However, young age treated rats (group II) indicated a non-significant difference when compared to group I. These changes were inconsistent with Abdel Motaal's (2006) results who found that Colchicine used (3 mg/kg body weight) for a few days can cause degeneration and necrosis of the sperm cells, Sertoli cells and Leydig cells with associated interstitial edema. In addition, debris was found within the lumen.

These results were in line with the findings of a study by Handel (1979), indicating the intratesticular administration of Colchicine for a short period (5 days) induced the degradation of microtubules. Consequently, the abnormal shape of the sperm which was associated with abnormal function.

In the present study, there was a cessation of the proliferation process of spermatocytes, and some sections showed lumen filled with debris and free from sperms. The findings were in agreement with previous studies (Kochman, 1998; Ben-Chitret et al., 1993), indicating that Colchicine can lead to oligospermia and even azoospermia through its effect on microtubules.

The results of the current study coincided with the results of a study by Abbas et al. (2016), who studied the effect of high dose (25mg/kg) Colchicine treatment in rats, and they found that Colchicine induced some pathological changes, including degeneration of germinal epithelium, and sloughing of the basement membrane of the tubules with an accumulation of the debris in the lumen as well as the cessation of the process of spermatogenesis.

These findings were in agreement with those of Shehab et al. (2014) and Elshama et al. (2013) results who recorded that Colchicine could enhance the degeneration of seminiferous tubules as well as Sertoli and Leydig cells with vacuolar degeneration of sperm cells with abnormal shape and cessation of proliferation process leading to azoospermia.

Similar to the results of the present study, Russel et al. (1981) stated that Colchicine could induce seminiferous tubules damage, sloughing of sperm cells within the lumen with cessation of sperm proliferation process, and degeneration of Sertoli cells in the testis of rats. In addition, they stated that the destruction of Sertoli cells was responsible for sloughing the neighboring germ cells into the lumen. Allard et al. (1993) studied the dose-related effect of Colchicine on rat testis and found that intratesticular administration of higher doses (40 μg) of Colchicine can lead to damage to the seminiferous tubules.

Colchicine has anti-inflammatory action as it reduces the production of free radicals and oxidative stress but it produces its effect by decreasing the polymerizing process of the microtubules leading to its destruction (Prins et al.,

2017; Golpour et al., 2021). A study by Sarica et al. (1995) indicated that Colchicine could affect spermatogenesis and lead to the cessation of the proliferation process and azoospermia.

The results of the present study were consistent with those reported by Correa et al. (2002). They studied the way Colchicine and carbendazim could affect testicular tissue in mice and they found that low dose intratesticular injected mice were normal while high dose treated mice showed damage in the seminiferous tubules. The associated morphometric study showed a significant statistical decline in the number of tubules due to sloughing the germinal epithelial layer.

## CONCLUSION

The present study concluded that high doses (3 mg/kg body weight) of Colchicine could produce tissue damage to the testis even when it is used for a short period (10 days), and the tissue damage was more severe in the elderly treated rats, compared to younger ones.

## DECLARATIONS

### Acknowledgments

We are glad to acknowledge animal house manager Dr. Ahmed Nadhem Hassan for his support.

### Authors' contribution

Rand Abdulateef Abdullah carried out the idea of the article, calculated the doses, handled the experimental animals, administered the medicine, and wrote down the whole article. Hana Khaleel Ismail was responsible for (results chapter), examining the tissue sections and identification of pathological changes in all groups. Ammar Ghanim Al-Haak carried out a morphometrical study, assessment of all parameters using a specialized camera, and analyzing morphometrical data, and graphs. All authors checked and approved the final version of the manuscript.

### Competing interests

No conflict of interest has been declared by the authors.

### Ethical considerations

Plagiarism, consent to publish, misconduct, data fabrication and or falsification, double publication and or submission, and redundancy have been checked by the authors.

## REFERENCES

- Abbas MF, Hassan OA, and Fakahany H (2016). Mitigating effect of vardenafil against Colchicine– induced testicular toxicity in adult male *albino* rats. *Ain Shams Journal of Forensic Medicine and Clinical Toxicology*, 27(2): 83-91. DOI: <https://www.doi.org/10.21608/AJFM.2016.18322>
- Abdel Motaal NAR (2006). Effect of Colchicine on the histology of spleen and testis of albino rats. *The Egyptian Journal of Hospital Medicine*, 23(1): 268-276. DOI: <https://www.doi.org/10.21608/EJHM.2006.17939>
- Allard EK, Johnson KJ, and Boekelheide K (1993). Colchicine disrupts the cytoskeleton of rat testis seminiferous epithelium in a stage-dependent manner. *Biology of Reproduction*, 48(1): 143-153. DOI: <https://www.doi.org/10.1095/biolreprod48.1.143>
- Angelidis Ch, Kotsialou Z, Kossyvakis Ch, Vrettou AR, Zacharoulis A, Kolokathis F, Kekeris V, and Giannopoulou G (2018). Colchicine pharmacokinetics and mechanism of action. *Current Pharmaceutical Design*, 24(6): 659-663. Available at: <https://www.doi.org/10.2174/1381612824666180123110042>
- Ben-Chetrit A, Ben-Chetrit E, Nitzan R, and Ron M (1993). Colchicine inhibits spermatozoal motility in vitro. *International Journal of Fertility and Menopausal Studies*, 38(5): 301-304. Available at: <http://pascal-francis.inist.fr/vibad/index.php?action=getRecordDetail&idt=3774788>
- Bertram GK, Masters SB, and Trevor AJ (2012). *Basic clinical pharmacology*. McGraw Hill., London, pp. 651-652. Available at: [http://health.sbmu.ac.ir/uploads/22\\_1809\\_1448957056226\\_Basic & clinical pharmacology-katzung-12th edition.pdf](http://health.sbmu.ac.ir/uploads/22_1809_1448957056226_Basic_%20clinical%20pharmacology-katzung-12th%20edition.pdf)
- Bhattacharyya B, Panda D, Gupta S, and Banerjee M (2008). Anti-mitotic activity of Colchicine and the structural basis for its interaction with tubulin. *Medicinal Research Reviews*, 28(1): 155-83. DOI: <https://www.doi.org/10.1002/med.20097>
- Correa LM, Nakai M, Strandgaard CS, Hess RA, and Miller MG (2002) Microtubules of the mouse testis exhibit differential sensitivity to the microtubule disruptors Carbendazim and Colchicine. *Toxicological Sciences*, 69(1): 175-82. DOI: <https://www.doi.org/10.1093/toxsci/69.1.175>

- Dasgeb B, Kornreich D, McGuinn K, Okon L, Brownell I, and Sackett DL (2018) Colchicine: An ancient drug with novel applications. *British Journal of Dermatology*, 178(2): 350-356. DOI: <https://www.doi.org/10.1111/bjd.15896>
- Elshama SS, Shehab GMG, El-Kenawy AE, Osman HEH, and Farag MM (2013). Role of Nigella Sativa Seeds on modulation testicular toxicity of Colchicine repeated use in adult *albino* rat. *Life Scientific Journal*, 10(4): 1629-1639. Available at: [http://www.lifesciencesite.com/ljsj/life1004/216\\_19846life1004\\_1629\\_1639.pdf](http://www.lifesciencesite.com/ljsj/life1004/216_19846life1004_1629_1639.pdf)
- Golpour M, Mousavi T, Ali mohammadi M, Mosayebian A, Shiran M, Alizadeh Navaei R, and Rafiei A (2021). The effectiveness of Colchicine as an anti-inflammatory drug in the treatment of coronavirus disease 2019: Meta-analysis. *International Journal of Immunopathology and Pharmacology*, 35: 1-8. DOI: <https://www.doi.org/10.1177/20587384211031763>
- Gómez GM, Garavito E, López AG, Villarraga AR, and Medina RP (2021). Colchicine: A potential therapeutic tool against COVID-19. Experience of 5 patients. *Reumatología Clínica*, 17(7): 371-375. DOI: <https://www.doi.org/10.1016/j.reumae.2020.05.008>
- Handel MA (1997). Effects of Colchicine on spermiogenesis in the mouse. *Journal of Embryology and Experimental Morphology*, 51(1): 73-83. Available at: <https://b2n.ir/a95078>
- Hasbani G, Jawad A, and Uthman I (2019). Update on the management of Colchicine resistant Familial Mediterranean Fever (FMF). *Orphanet Journal of Rare Diseases*, 14: 244. DOI: <https://www.doi.org/10.1186/s13023-019-1201-7>
- Kamel NA, Ismail NM, Yahia IS, and Aboshanab KM (2021). Potential role of Colchicine in combating COVID-19 cytokine storm and its ability to inhibit protease enzyme of sars-cov-2 as conferred by molecular docking analysis. *Medicina*, 58(1): 20. DOI: <https://www.doi.org/10.3390/medicina58010020>
- Kirkwood Br (1988). *Essentials of medical statistics*. First edition, Black well, Scientific publication, Oxford, pp. 43-56.
- Kurek J, Myszkowski K, Kozaryn IO, Kurant A, Kamińska E, Szulc M, Rubiś B, Kaczmarek M, Mikołajczak PŁ, and Murias M (2021). Cytotoxic, analgesic and anti-inflammatory activity of Colchicine and its C-10 sulfur containing derivatives. *Scientific Reports*, 11(1): 9034. DOI: <https://www.doi.org/10.1038/s41598-021-88260-1>
- Leung YY, Hui LLY, and Kraus VB (2015). Colchicine-update on mechanisms of action and therapeutic uses. *Seminars in Arthritis and Rheumatism*, 45(3): 341-350. DOI: <https://www.doi.org/10.1016/j.semarthrit.2015.06.013>
- Li Y, Zhang Y, Lu J, Yin Y, Xie J, and Xu B (2021). Anti-inflammatory mechanisms and research progress of Colchicine in atherosclerotic therapy. *Journal of Cellular and Molecular Medicine*, 25(17): 8087-8094. DOI: <https://www.doi.org/10.1111/jcmm.16798>
- Liang JC, Hsu TC, and Gay M (1985). Response of murine spermatocytes to the metaphase arresting effect of several mitotic arrestants. *Experimentia*, 41: 1586-1588. DOI: <https://www.doi.org/10.1007/BF01964819>
- Lopes I, Bonjorno LP, Giannini MC, Amaral NB, Menezes PI, Dib SM, Gigante SL, Benatti MN, Rezek UC, Filho LE et al. (2021). Beneficial effects of Colchicine for moderate to severe COVID-19: A randomised, double-blinded, placebocontrolled clinical trial. *Rheumatic and Musculoskeletal Diseases Open*, 7: e001455. Available at: <https://rmdopen.bmj.com/content/rmdopen/7/1/e001455.full.pdf>
- Martínez GJ, Celermajer DS, and Patel S (2017). The NLRP3 inflammasome and the emerging role of Colchicine to inhibit atherosclerosis-associated inflammation. *Review article*. *Atherosclerosis*, 269: 262-271. DOI: <https://www.doi.org/10.1016/j.atherosclerosis.2017.12.027>
- Maxwell MJ, Muthu P, and Pritty PE (2002). Accidental colchicine overdose. A case report and literature review. *Emergency Medicine Journal*, 19(3): 265-267. DOI: <http://www.doi.org/10.1136/emj.19.3.265>
- Mizutani T, Masuda M, Nakai E, Furumiya K, Togawa H, Nakamura Y, Kawai Y, Nakahira K, Shinkai S, and Takahashi K (2008). Genuine functions of P-glycoprotein (ABCB1). *Current Drug Metabolism*, 9(2): 167-74. DOI: <https://www.doi.org/10.2174/138920008783571756>
- Niel E and Scherrmann JM (2006). Colchicine today. *Joint Bone Spine*, 73: 672-678. DOI: <https://www.doi.org/10.1016/j.jbspin.2006.03.006>
- Prins KW, Tian L, Wu D, Thenappan, Metzger JM, and Archer SL (2017). Colchicine depolymerizes microtubules, increases junctophilin-2, and improves right ventricular function in experimental pulmonary arterial hypertension. *Journal of the American Heart Association*, 6(6): e006195. DOI: <https://www.doi.org/10.1161/JAHA.117.006195>
- Reprod H and Kochman RH (1998). The effect of Colchicine treatment on sperm production and function: A review. *Human Reproduction*, 13(2): 360-362. DOI: <https://www.doi.org/10.1093/humrep/13.2.360>
- Russell LD, Malone JP, and MacCurdy D (1981). Effect of the microtubule disrupting agents, Colchicine and vinblastine, on seminiferous tubule structure in the rat. *Tissue and Cell*, 13(2): 349-67. DOI: [https://www.doi.org/10.1016/0040-8166\(81\)90010-0](https://www.doi.org/10.1016/0040-8166(81)90010-0)
- Sardana K, Sinha S, and Sachdeva S (2020). Colchicine in dermatology: Rediscovering an old drug with novel uses. *Indian Dermatology Online Journal*, 11(5): 693-700. DOI: [https://www.doi.org/10.4103/idoj.IDOJ\\_475\\_20](https://www.doi.org/10.4103/idoj.IDOJ_475_20)
- Sarica K, Süzer O, Gürler A, Baltacı S, Ozdiler E, and Dinçel C (1995). Urological evaluation of Behçet patients and the effect of Colchicine on fertility. *European Urology*, 27(1): 39-42. DOI: <https://www.doi.org/10.1159/000475121>

- Saxena S, Tandon S, Sardana K, and Bajaj S (2019). Herpetiform aphthous genital ulcers misdiagnosed as herpes genitalis in a young male and their effective response to colchicine therapy. *International Journal of STD & AIDS*, 30(13): 1340-1343. DOI: <https://www.doi.org/10.1177/0956462419870672>
- Scarsi M, Piantoni S, Colombo E, Airó P, Richini D, Miclini M, Bertasi V, Bianchi M, Bottone D, Civelli P et al. (2020). Association between treatment with Colchicine and improved survival in a single-center cohort of adult hospitalized patients with COVID-19 pneumonia and acute respiratory distress syndrome. *Annals of the Rheumatic Diseases*, 79(10): 1286-1289. DOI: <https://www.doi.org/10.1136/annrheumdis-2020-217712>
- Schenone AL and Menon V (2018). Colchicine in pericardial disease: From the underlying biology and clinical benefits to the drug-drug interactions in cardiovascular medicine. *Current Cardiology Reports*, 20(8): 62. DOI: <https://www.doi.org/10.1007/s11886-018-1008-5>
- Schlesinger N, Schumacher R, Catton M, and Maxwell L (2006). Colchicine for acute gout. *Cochrane Database Systemic Review*, 2006: 4. DOI: <https://www.doi.org/10.1002/14651858.CD006190>
- Shehab MI, Zaki NN, Boutros ME, Emam HT, and El-Kawas AB (2014). The possible protective effect of sildenafil on Colchicine-induced infertility in rats. *International Journal of Advanced Research*, 2(5): 939-951. Available at: [https://www.journalijar.com/uploads/895\\_IJAR-3373.pdf](https://www.journalijar.com/uploads/895_IJAR-3373.pdf)
- Siak J, Flint N, Shmueli HG, Siegel RJ, and Rader F (2021). The use of Colchicine in cardiovascular diseases: A systematic review. *The American Journal of Medicine*, 134(6): 735-744. DOI: <https://www.doi.org/10.1016/j.amjmed.2021.01.019>
- Vaidya K, Martínez G, and Patel S (2019). The role of Colchicine in acute coronary syndromes. *Clinical Therapeutics*, 41(1): 11-20. DOI: <https://www.doi.org/10.1016/j.clinthera.2018.07.023>
- Vitiello A, Ferrara F, Pelliccia C, Granata G, and Porta RL (2020). Cytokine storm and Colchicine potential role in fighting SARS-CoV-2 pneumonia. *Italian Journal of Medicine*, 14(2): 88-94. Available at: [file:///C:/Users/kavakshop/Downloads/pgranata,+IJM\\_14\\_2\\_1284\\_opt.pdf](file:///C:/Users/kavakshop/Downloads/pgranata,+IJM_14_2_1284_opt.pdf)
- Yurdakul S, Mat C, Tüzün Y, Ozyazgan Y, Hamuryudan V, Uysal O, Senocak M, and Yazici H (2001). A double-blind trial of Colchicine in Behçet's syndrome. *Arthritis Rheumatology*, 44(11): 2686-2692. Available at: <https://pubmed.ncbi.nlm.nih.gov/11710724/>