



Macroscopic Differences of Pig Eye after Death: A Veterinary Forensic Study

Albiruni Haryo^{1,2} , Rini Widayanti³ , Tri Wahyu Pangestiniingsih^{4*} , and AYPBC Widyatmoko⁵

¹Doctoral Student, Faculty of Veterinary Medicine, Universitas Gadjah Mada, Indonesia

²Laboratory of Pathology, Faculty of Veterinary Medicine, Universitas Brawijaya, Indonesia

³Department of Biochemistry, Faculty of Veterinary Medicine, Universitas Gadjah Mada, Indonesia

⁴Department of Anatomy, Faculty of Veterinary Medicine, Universitas Gadjah Mada, Indonesia

⁵National Research and Innovation Agency (BRIN), Jakarta, Indonesia

*Corresponding author's Email: estifkh@ugm.ac.id

ABSTRACT

The study of veterinary forensics is a field of science that is developing rapidly in the world of veterinary medicine. Veterinary forensics plays a crucial role in investigating and resolving cases involving animals, either as subjects or objects in incidents and ensuring the collection of all possible biological and physical evidence. Given the close relationship between humans and animals, numerous significant cases arise that are pertinent to veterinary forensics. The current research aimed to determine early post-mortem changes in pigs, providing insights into animal mortality in real-world scenarios. Observations were made on seven male Yorkshire pigs, aged 3 months old, with an average weight of 30.1 kg. Pigs were observed at four different post-mortem intervals, including 2, 4, 6, and 8 hours after death, with initial observations at the time of death serving as the control. Observations of changes in the eye sclera, eye lens, eyeball temperature, and eyeball pressure were carried out at each time interval. Results at the 2nd and 4th hours post-mortem showed no macroscopic changes in the eye sclera and eye lens, but there were changes in eye pressure. By the 6th and 8th hours, changes in the sclera and eye lens showed desiccation in the area of the sclera and the eye lens, which became increasingly cloudy. The eyeball temperature measurement values from the 2nd to 8th hour of the study revealed a significant decrease in eyeball pressure. The results of this study indicated observable changes in the eyes can be used as a basic alternative method for calculating the introductory post-mortem interval in animals in the future. There was a significant decrease in eyeball temperature, and eyeball compactness, as significant differences in the eye sclera, and eye lens at 2, 4, 6, and 8 hours post-mortem, compared to the time of death. These variables offer crucial insights into early post-mortem changes in pigs, using the eyes as the primary focus of observation.

Keywords: Death, Eye, Forensic study, Pig

INTRODUCTION

The study of veterinary forensics is essential in veterinary science, especially in identifying and investigating crimes against animals. The area that received special attention in this study has been the eye organ. The eyes of different animals are often the focus of veterinary forensic cases and serve as a rich source of post-mortem information (Ruiz-Ederra et al., 2005). Several factors make the eye an important subject in veterinary forensic studies, including its use in identifying animals involved in crimes through microstructure analysis and other unique signs present in the eye structure (Ang et al., 2021). In several important cases, histopathological and microscopic examination of the eye organs can provide a relatively clear picture of the animal's health condition before death, including the presence of infection, inflammation, or other pathological disorders (Sarmiento et al., 2023). The eye offers numerous advantages in forensic investigations due to its capabilities in identification, visual recording, DNA analysis, and health information retrieval (Ang et al., 2021). The current study aimed to determine the macroscopic differences in pig eyes at various post-mortem intervals. Determining the time of death of animals in the field was a critical need that must immediately receive an easy and effective solution.

MATERIALS AND METHODS

Ethical approval

All procedures conducted on animals were in accordance with the ethical standards of the institution, and the current study was approved by the Animal Care and Use Committee (Komisi Etik Penelitian) Universitas Brawijaya, Indonesia (No. 153 KEP UB 2022).

Sampling

A total of seven healthy male Yorkshire pigs, aged 3 months old, and weighing 30 kg were sourced from pig farms in Kromengan, Malang, East Java, Indonesia. These pigs were euthanized using an overdose of Ketamine 10% Inj. (Dutch, Holland) 10 mg/kg and Xylazine (Interchemie, Holland) 6mg/kg following the standard AVMA Guidelines for

ORIGINAL ARTICLE
Received: March 21, 2024
Revised: April 26, 2024
Accepted: May 14, 2024
Published: June 30, 2024

the Euthanasia of Animals (AVMA, 2020). Euthanization and observation were carried out at the animal burial site in Malang City, East Java, Indonesia. Shortly after euthanasia was successfully carried out, the pig's body was laid down by manipulation with an eye retractor on both right and left eyes; observations were made at 2, 4, 6, and 8 hours post-death. The observed changes are macroscopic changes in the eyeball, eye sclera, eye lens, eyeball temperature, and eye compactness. This research was conducted at the Central Laboratory for Research and Diagnostics of Satwa Sehat Indonesia, Malang, East Java, Indonesia.

Preparation

Observations were conducted in an open-air environment in October 2023, with an environmental temperature of 25-28°C, air humidity of 80%, and a wind speed of 0 km/hour. Observation times with obvious weather conditions were carried out at 08.00 am and 04.00 pm. Macroscopic observations were carried out using a professional camera, (Canon 700D, Japan) to observe the eye sclera and eye lens. Eyeball temperature was observed using a noncontact infrared thermometer (HT 820D, China), and eye compactness was carried out using animal eye tonometry (Tonometer Schiotz, Pakistan).

Statistical analysis

The obtained data was analyzed using inferential statistical analysis to compare the different post-mortem intervals. The relationship between the time of death and macroscopic changes was carried out carefully. Multiple regression analysis ($Y = a + b_1 X_1 + b_2 X_2 + \dots + b_n X_n$) was employed, starting with the coefficient of determination, F-test, and t-test. The regression equation was carried out at the end of the analysis to ensure the accuracy of the regression equation's interpretation by confirming its significance. The relationship between the time of death and macroscopic changes was analyzed carefully. The time intervals of death used in this study included 2, 4, 6, and 8 hours after death occurred. Observations were made by observing macroscopic changes in the eyeball, eye sclera, eye lens, eyeball temperature, and eye compactness.

RESULTS

Observations of changes in the eyes of Yorkshire pigs aged 3 months after euthanization using a combination of Ketamine and Xylazine were summarized in Table 1. Each parameter explains how the macroscopic changes in the sclera, eye lens, eyeball temperature, and eyeball pressure show precise results. Figure 1 shows the observation method carried out at the control and observation time at 8 hours after death. Data for the measured parameter, including the use of a camera, infrared thermometer, and tonometry, are presented in Table 1 and Figure 1.

The results that indicated changes in the sclera began to occur between 4 and 8 hours after death. Changes in the eye lens occurred twice 2 and hours after death. The results multiple regression test indicated significant changes in eyeball temperature ($p < 0.05$) and eyeball pressure ($p < 0.05$) using Minitab 18 software.

Table 1. The pig eyeball parameters at observation times

Parameter	Sample	Control	Time of death			
			2 Hours	4 Hours	6 Hours	8 Hours
Macroscopic change - sclera	Pig 01	White	White	Cloudy Black	Cloudy Black	Cloudy Black
	Pig 02	White	White	Cloudy Black	Cloudy Black	Cloudy Black
	Pig 03	White	White	Cloudy Black	Cloudy Black	Cloudy Black
	Pig 04	White	White	Cloudy Black	Cloudy Black	Cloudy Black
	Pig 05	White	White	Cloudy Black	Cloudy Black	Cloudy Black
	Pig 06	White	White	Cloudy Black	Cloudy Black	Cloudy Black
Macroscopic change - lens	Pig 01	Clear	Cloudy White	Cloudy White	Cloudy White	White
	Pig 02	Clear	Cloudy White	Cloudy White	Cloudy White	White
	Pig 03	Clear	Cloudy White	Cloudy White	Cloudy White	White
	Pig 04	Clear	Cloudy White	Cloudy White	Cloudy White	White
	Pig 05	Clear	Cloudy White	Cloudy White	Cloudy White	White
	Pig 06	Clear	Cloudy White	Cloudy White	Cloudy White	White
Eyeball temperature (°C)	Pig 01	38.0 °C	37.5 °C	35.2 °C	33.7 °C	32.3 °C
	Pig 02	38.1 °C	37.2 °C	36.5 °C	33.5 °C	32.5 °C
	Pig 03	38.0 °C	36.9 °C	36.8 °C	33.6 °C	33.2 °C
	Pig 04	38.2 °C	37.6 °C	35.6 °C	33.5 °C	32.8 °C
	Pig 05	38.0 °C	37.0 °C	36.6 °C	34.5 °C	33.9 °C
	Pig 06	38.2 °C	37.6 °C	35.9 °C	33.8 °C	32.5 °C
Eyeball compactness (mm/Hg)	Pig 01	15.2	14.7	12.5	11.3	11.0
	Pig 02	15.3	13.9	12.1	11.5	10.9
	Pig 03	15.2	14.8	11.6	11.7	10.8
	Pig 04	15.2	14.2	12.4	10.8	10.2
	Pig 05	15.7	14.6	13.0	11.1	10.2
	Pig 06	15.4	14.8	13.2	12.1	11.1

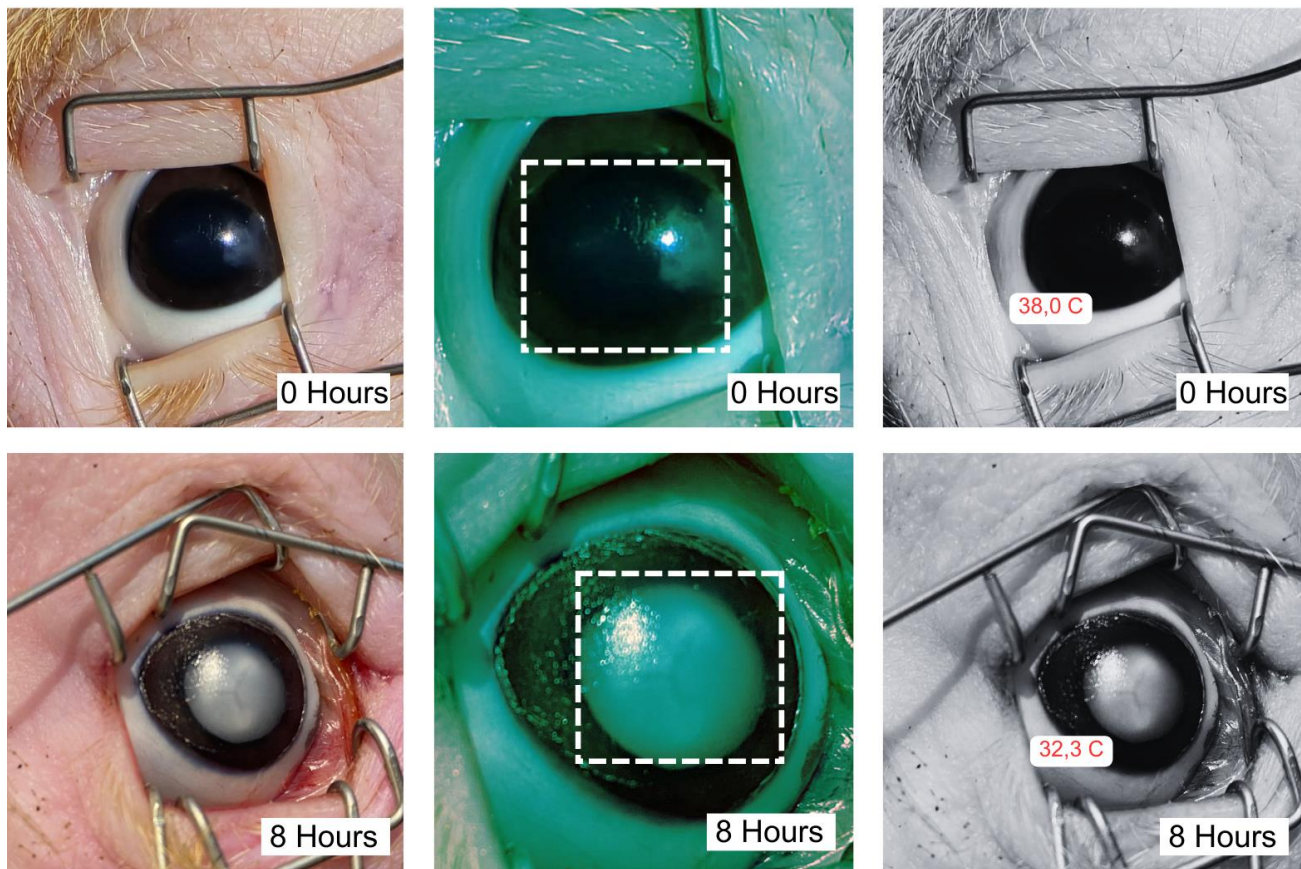


Figure 1. The observations of the sclera, lens, and eyeball temperature immediately after death and 8 hours post-mortem

DISCUSSION

Determining the time of death in animals is crucial for legal proceedings, often referred to as post-mortem interval analysis (Shrestha *et al.*, 2023). This necessity arises due to animals being involved in various cases where evidence of death timing is essential. Reported cases of animal death encompass a range of species, including dogs, cats, cows, horses, and other wildlife (Erlandsson and Munro, 2007; Ushine *et al.*, 2020). In the present study, homogenization of pig samples was carried out using male Yorkshire pigs aged 3 months with an average body weight of 30.1 kg. Pigs were used as experimental animals, similar to other nutritional research (Roura *et al.*, 2016), heart failure models (Dixon and Spinale, 2009), and wound tissue healing (Kuo *et al.*, 2022). Pigs are frequently chosen for research models due to factors such as their abundant population and their non-protected status, ensuring ethical considerations are met (Swindle *et al.*, 2012).

The initial data from pigs used as controls were compared with observation times at 2, 4, 6, and 8 hours with immediate death time serving as a control. With four variables observed in this research, macroscopic changes in the sclera, lens, eyeball temperature, and eyeball pressure provided a practical picture. They are made easy to use as practical samples for basic data in the field. Following death, pigs undergo various phases of post-mortem changes, including algor mortis, rigor mortis, livor mortis, and decomposition, aligning with reports that natural changes occur in the body for 12 to 24 hours post-death (Brooks, 2016). These changes in death can affect all parts of the animal's body, including the eyes (Ang *et al.*, 2021). The eye was selected as a crucial organ in the post-mortem examination process for several reasons. It stores significant data within the body and exhibits minimal developmental changes in both humans and animals. Changes experienced by the eye, such as macroscopic changes in the sclera and eye lens, are associated with changes in metabolic processes in the eye, which gradually stop after death occurs (Gerometta *et al.*, 2019). The desiccation process in the sclera layer of the eye is also associated with the cessation of the supply of fluid secretion from the lacrimal gland (Conrady *et al.*, 2016). It is closely related to an increase in cytokines and antigen-presenting cells (APCs) in the conjunctival area (Alam *et al.*, 2021).

The changes observed in the eye lens shortly after death are attributed to several factors. The eye lens contains specific proteins, particularly crystallin, which are crucial for maintaining lens transparency (Andley, 2007). However,

once the body's maintenance and repair mechanisms cease functioning post-mortem (Miller and Zachary, 2017), these proteins can then aggregate, leading to clumping. This aggregation disrupts the lens's transparency, resulting in a cloudy appearance. Additionally, the cells surrounding the lens cease vital functions such as cleaning or renewing lens components (Andley, 2008). With this condition, materials that are typically removed or replaced during cellular maintenance can accumulate in the lens, further contributing to cloudiness (Gerometta et al., 2019).

The decrease in eyeball temperature is associated with the cessation of metabolic processes affecting all organs, including the eyes (Kaliszan et al., 2010). This decrease in temperature is observed in pigs and other experimental animals in research settings. Furthermore, in this study, eyeball pressure demonstrated a significant decrease over time. Eyeball pressure reflects the integrity of the eye and the potential for damage. A decrease in eye pressure is observed in various animal species post-mortem, as seen in cattle (Gerometta et al., 2019), rabbits and rats (Lee et al., 2022), as well as mice (Kim et al., 2007). In this study, the changes that occur in the first 8 hours after pig death illustrate fundamental mortality changes that can be used in effective and economical examination methods in the field and serve as a tool to prove the estimated time of death of the animal.

CONCLUSION

The findings of this study confirmed a significant decrease in the compactness and temperature of the eyeball, the lens became white and cloudy, and the sclera became cloudy black at various time intervals after pig death. The findings suggest that further research should be carried out on changes over a more varied observation period from 36-72 hours.

DECLARATIONS

Funding

Funding was provided by Doctoral Dissertation Research (PDD) by the Indonesian Ministry of Education and Culture

Number is 089/E5/PG.02.00PT/2022;1884/UN1/DITLIT/Dit-Lit/PT.01.03/2022

Authors' contributions

Albiruni Haryo contributed to collecting samples and statistically analyzing data. Rini Widayanti, Tri Wahyu Pangestiningih, AYPBC Widyatmoko analyzed data, and formatted and edited the manuscript. All authors discussed the results commented on the manuscript, and gave final approval for the final version of the manuscript.

Ethical considerations

Ethical issues (including plagiarism, consent to publish, misconduct, data fabrication and/or falsification, double publication and/or submission, and redundancy) have been checked by all the authors.

Conflict of interests

The authors have no conflict of interest to present.

Availability of data and materials

All data of the current study are available in the present article.

REFERENCES

- Alam J, de Paiva CS, and Pflugfelder SC (2021). Desiccation induced conjunctival monocyte recruitment and activation – Implications for keratoconjunctivitis. *Frontiers in Immunology*, 12: 701415. DOI: <https://www.doi.org/10.3389/fimmu.2021.701415>
- American veterinary medicine association (AVMA) (2020). AVMA guidelines for the euthanasia of animals, 2020 Edition. pp. 1-33. Available at: <https://www.avma.org/sites/default/files/2020-02/Guidelines-on-Euthanasia-2020.pdf>
- Andley UP (2007). Crystallins in the eye: Function and pathology. *Progress in Retinal and Eye Research*, 26(1): 78-98. DOI: <https://www.doi.org/10.1016/j.preteyeres.2006.10.003>
- Andley UP (2008). The lens epithelium: Focus on the expression and function of the alpha-crystallin chaperones. *The International Journal of Biochemistry & Cell Biology*, 40(3): 317-323. DOI: <https://www.doi.org/10.1016/j.biocel.2007.10.034>
- Ang JL, Collis S, Dhillon B, and Cackett P (2021). The eye in forensic medicine: A narrative review. *Asia-Pacific Journal of Ophthalmology*, 10(5): 486-494. DOI: <https://www.doi.org/10.1097/APO.0000000000000426>
- Brooks JW (2016). Postmortem changes in animal carcasses and estimation of the postmortem interval. *Veterinary Pathology*, 53(5): 929-940. DOI: <https://www.doi.org/10.1177/0300985816629720>

- Conrady CD, Joos ZP, and Patel BCK (2016). Review: The lacrimal gland and its role in dry eye. *Journal of Ophthalmology*, 2016: 7542929. DOI: <https://www.doi.org/10.1155/2016/7542929>
- Dixon JA and Spinale FG (2009). Large animal models of heart failure: A critical link in the translation of basic science to clinical practice. *Circulation: Heart Failure*, 2(3): 262-271. DOI: <https://www.doi.org/10.1161/CIRCHEARTFAILURE.108.814459>
- Erlandsson M and Munro R (2007). Estimation of the post-mortem interval in beagle dogs. *Science & Justice*, 47(4): 150-154. DOI: <https://www.doi.org/10.1016/j.scijus.2007.09.005>
- Gerometta R, Larroza GO, Pimpinella P, and Genero S (2019). Variation of the intraocular pressure in relation to time of death: Contribution to the determination of the true postmortem interval (PMI). *Revista Mexicana De Medicina Forense Y Ciencias De La Salud*, 4(1): 15-23. DOI: <https://www.doi.org/10.25009/revmedforense.v4i1.2604>
- Kuo TY, Huang CC, Shieh SJ, Wang YB, Lin MJ, Wu MC, and Huang LLH (2022). Skin wound healing assessment via an optimized wound array model in Miniature pigs. *Scientific Reports*, 12(1): 445. DOI: <https://www.doi.org/10.1038/s41598-021-03855-y>
- Kim CY, Kuehn MH, Anderson MG, and Kwon YH (2007). Intraocular pressure measurement in mice: A comparison between Goldmann and rebound tonometry. *Eye*, 21(9): 1202-1209. Available at: <https://www.nature.com/articles/6702576>
- Kaliszan M, Hauser R, Buczynski J, Jankowski Z, Raczynska, and Wighton GK (2010). The potential use of the eye temperature decrease in determining the time of death in the early postmortem period studies in pigs. *The American Journal of Forensic Medicine and Pathology*, 31(2): 162-164. DOI: <https://www.doi.org/10.1097/PAF.0b013e3181d8e2e7>
- Lee LY, Hsu JH, Fu HI, Chen CC, and Tung KC (2022). Lowering the intraocular pressure in rats and rabbits by cordyceps cicadae extract and its active compounds. *Molecules*, 27(3): 707. DOI: <https://www.doi.org/10.3390/molecules27030707>
- Miller MA and Zachary JF (2017). Mechanisms and morphology of cellular injury, adaptation, and death. *Pathologic Basis of Veterinary Disease*, 2: e19. DOI: <https://www.doi.org/10.1016/B978-0-323-35775-3.00001-1>
- Roura E, Koopmans S, Lalles JP, Huerou Luron IL, Jager ND, Schuurman T, and Val Laillet D (2016). Critical review evaluating the pig as a model for human nutritional physiology. *Nutrition Research Reviews*, 29(1): 60-90. DOI: <https://www.doi.org/10.1017/S0954422416000020>
- Ruiz-Ederra J, García M, Hernández M, Urcola H, Hernández, Barbáchano EH, Araiz, and Vecino E (2005). The pig eye as a novel model of glaucoma. *Experimental Eye Research*, 81(5): 561-569. DOI: <https://www.doi.org/10.1016/j.exer.2005.03.014>
- Sarmiento DMM, Montaña Ó LR, Castiblanco JDA, and Rodríguez CJC (2023). The impact of horizontal eye movements versus intraocular pressure on optic nerve head biomechanics: A tridimensional finite element analysis study. *Heliyon*, 9(2): E13634. DOI: <https://www.doi.org/10.1016/j.heliyon.2023.e13634>
- Shrestha R, Kanchan T, and Krishan K (2023). Methods of estimation of time since death. *Stat Pearls Publishing*, pp. 1-8. Available at: <http://www.ncbi.nlm.nih.gov/books/NBK549867/>
- Swindle MM, Makin A, Herron AJ, Clubb FJ, and Frazier KS (2012). Swine as models in biomedical research and toxicology testing. *Veterinary Pathology*, 49(2): 344-356. DOI: <https://www.doi.org/10.1177/0300985811402846>
- Ushine N, Tanaka A, and Hayama S (2020). Investigation of causes of death in wildlife using veterinary molecular and wound analysis methods. *Journal of Veterinary Medical Science*, 82(8): 1173-1177. <https://www.doi.org/10.1292/jvms.19-0394>

Publisher's note: Scienceline Publication Ltd. remains neutral with regard to jurisdictional claims in published maps and institutional affiliations.



Open Access: This article is licensed under a Creative Commons Attribution 4.0 International License, which permits use, sharing, adaptation, distribution and reproduction in any medium or format, as long as you give appropriate credit to the original author(s) and the source, provide a link to the Creative Commons licence, and indicate if changes were made. The images or other third party material in this article are included in the article's Creative Commons licence, unless indicated otherwise in a credit line to the material. If material is not included in the article's Creative Commons licence and your intended use is not permitted by statutory regulation or exceeds the permitted use, you will need to obtain permission directly from the copyright holder. To view a copy of this licence, visit <https://creativecommons.org/licenses/by/4.0/>.