



# Effects of Bromelain Loaded with Gold Nanoparticles on Histopathological and Immunohistochemical Parameters in Albino Mice with Testicular Damage

Saddama Saed Faraj<sup>1</sup>, Rana Hanan Khudhair Al-Rubaye\*<sup>1</sup>, Baydaa Hussain Mutlak<sup>1</sup>, and Entidhar Mohammed Mnati<sup>1</sup>

Department of Biology, College of Education for Pure Sciences/ Ibn Al-Haitham, University of Baghdad, Iraq

\*Corresponding author's Email: [rana.h.k@ihcoedu.uobaghdad.edu.iq](mailto:rana.h.k@ihcoedu.uobaghdad.edu.iq)

## ABSTRACT

Carbon tetrachloride (CCl<sub>4</sub>) has been demonstrated to induce testicular damage via oxidative stress. Bromelain (Br), a proteolytic enzyme known for its biological activities and pharmacological properties, exhibits limited absorption owing to its low solubility and bioavailability. The present study aimed to investigate the histological and immunohistochemical effects of bromelain conjugated with gold nanoparticles (AuNPs) on the testis histology of albino mice treated with CCl<sub>4</sub>. Thirty-five male albino mice (*Mus musculus*), with an average age of 9 weeks, were randomly divided into five groups, each containing seven mice. The experiment was prolonged for four weeks. The first group (G1) was the control group, the second group (G2) received weekly sub-peritoneal injections of CCl<sub>4</sub> until the end of the experiment, and the third group (G3) received an oral dose of Au-NPs solution. The fourth group (G4) received injections of CCl<sub>4</sub>; one hour later, the mice were given an oral dose of 300 mg/kg bromelain. The fifth group (G5) received an injection of CCl<sub>4</sub>; subsequently, the mice received the same oral dosage of 300 mg/kg Au-NPs-bromelain after 60 minutes. The mice's testes were sampled to evaluate histopathological alterations and immunohistochemical markers, particularly Ki-67 and caspase-9. The present results indicated that mice treated with CCl<sub>4</sub> displayed a range of histological alterations, including testicular damage, degeneration in seminiferous tubules, vacuolation, and loss of germ cells. Furthermore, the immunohistochemistry study demonstrated that Ki-67 intensity decreased while caspase-9 intensity increased in groups G2 and G4 compared to the control group. Bromelain loaded with gold nanoparticles at a dosage of 300 mg/kg exhibited a notable reduction in the harmful effects of CCl<sub>4</sub> on the testicular tissue of mice by restoring the histological structure, enhancing the Ki-67 proliferation protein, and suppressing the apoptotic cascade protein indicated by caspase 9.

**Keywords:** Bromelain, Carbon tetrachloride, Caspase, Gold nanoparticle

## INTRODUCTION

Carbon tetrachloride (CCl<sub>4</sub>) is a colorless chemical molecule that is volatile, stable, and rapidly absorbed by both people and animals. It is released into the environment by toxic gas emissions such as tetrachloromethane, polluting soil, water, and air (Sherry et al., 2018). These industrial pollutants can enter the body via multiple routes and are known to damage different organs by altering cellular and tissue structure and functions (Sönmez et al., 2014). Although the liver is the main site of CCl<sub>4</sub> toxicity and carcinogenesis, it also adversely affects the structure and function of other body organs, including the brain, lung, kidney, and testis (Unsal et al., 2021). The CCl<sub>4</sub> exposure is known to induce testicular toxicity by reducing testicular and seminal vesicle weight, quantity, and quality of semen, and hormone levels, such as testosterone, follicle-stimulating hormone, and luteinizing hormone, all of which are critical for spermatogenesis (Rahmouni et al., 2019). Bromelain is a complex mixture of proteolytic enzymes derived from plants of the Bromeliaceae family, mostly extracted from the pineapple (*Ananas comosus*), being the most common species in this family (Varilla et al., 2021). Bromelain can scavenge free radicals and prevent lipids from oxidizing due to its antioxidant properties (Kansakar et al., 2024). Numerous cellulases, phosphatases,  $\beta$ -glucosidases, peroxidases, thiol endopeptidases, glycoproteins, and protease inhibitors are found in bromelain (Ali et al., 2024).

ORIGINAL ARTICLE  
Received: September 20, 2025  
Revised: October 25, 2025  
Accepted: November 23, 2025  
Published: December 31, 2025

In recent years, gold nanoparticles (AuNPs) have become more prominent because of their improved and unique physical, chemical, and biological properties (Rajkumar *et al.*, 2025). Conjugating proteins to nanoparticles can enhance their stability, protect them from enzymatic digestion, as well as increase solubility and permeability while decreasing toxicity (Brito *et al.*, 2021). Bromelain's large size, proteolytic nature, and water-soluble properties hinder its cell penetration, but formulating it into nanoemulsions or nanoparticles can improve its intracellular delivery for therapeutic purposes by protecting the enzyme from inactivation and facilitating entry across cell membranes (Rohmah *et al.*, 2021). Although the direct association between bromelain and the proliferation protein Ki-67 in the testis is not well established, it may have an indirect effect by altering oxidative stress, inflammation, and cell proliferation (Yakut *et al.*, 2025). Ki-67 is a nuclear DNA-binding protein, expressed in all vertebrates, often used as a marker to evaluate cell proliferation due to its specific localization to actively cycling cells (Zhao *et al.*, 2018). Consequently, Ki-67 expression levels in the testis are a typical marker of spermatogenic cell proliferation and can also be used to evaluate the proliferation of spermatogenic cells (Menon *et al.*, 2019). Apoptosis serves as a fundamental quality control mechanism in the testis, regulating germ cell development from genital differentiation through fertilization. It ensures the proper function of male germ cells and maintains a healthy ratio between germ and Sertoli cells (Asadi *et al.*, 2021). The cytoplasm possesses a cysteine protease called caspase, which is one of the first caspases. Caspase-9 is essential to the intrinsic apoptotic process, which can receive upstream apoptotic signals to activate downstream caspases (Yu *et al.*, 2024). Given the antioxidant properties of bromelain and the drug delivery capabilities of AuNPs, the present study aimed to investigate the effect of bromelain-loaded AuNPs on testicular histology and bromelain bioavailability in albino mice injured by carbon tetrachloride.

## MATERIALS AND METHODS

### Ethical approval

The present study has been approved by the ethical committee of the biology department at the University of Baghdad, College of Education for Pure Sciences/ Ibn Al-Haitham in Baghdad, Iraq. On 19/1/2025, the authorization was acquired under reference number EC-84.

### Materials and reagents

Carbon tetrachloride, trisodium citrate, bromelain (EC:3.4.22.32), and chloroauric trihydrate ( $\text{HAuCl}_4 \cdot 3\text{H}_2\text{O}$ ) were supplied by Sigma-Aldrich (St. Louis, USA). Only analytical-grade reagents were used, as all materials mentioned had sufficient purity for quantitative chemical analysis. De-ionized water was utilized for all laboratory and reaction requirements.

### AuNPs and Br-AuNPs preparation

A gold stock solution was prepared by boiling 0.1 mM of aqueous  $\text{HAuCl}_4 \cdot 3\text{H}_2\text{O}$ , then 1% trisodium citrate was added, and the solution was left to develop the red nanoparticle solution (Abeed *et al.*, 2023). Then bromelain was added to AuNPs at a ratio of 1:5 v/v, meaning that for every milliliter of bromelain, 5 mL of gold solution was added (Ali *et al.*, 2024).

### Preparation of the carbon tetrachloride solution

To produce the solution, 1 mL of concentrated pure  $\text{CCl}_4$  was diluted with 3 mL of olive oil in a glass beaker. The mixture was then thoroughly combined and was stored at room temperature until further utilization within two days (Abeed and Al-Shmgani, 2024).

### Experimental design and animals

The study involved 35 male albino mice, *Mus musculus*, aged 8-10 weeks and weighing  $26 \pm 5$  g, sourced from the Biotechnology Research Center at Al Nahrain University, Iraq. The animals were placed inside clean, sterilized breeding cages with a litter of sawdust in a well-ventilated room with a temperature ranging from  $5 \pm 25^\circ\text{C}$  and an average of 12 hours of light versus 12 hours of darkness. The mice were supplied with a standard diet, a commercially available rodent chow pellet providing approximately 3.9 kcal of metabolizable energy (ME) per gram and a crude protein (CP) content of 15%, in addition to drinking water. The cages (50×20×30) in the breeding room were cleaned and sterilized on a weekly schedule. The experiment was extended for four weeks. Animals were separated into five groups, seven in each. The first group (G1) was the control group, which received normal saline daily for 4 weeks. Mice in Group G2 were injected subperitoneally with 0.1 mL of  $\text{CCl}_4$  once a week at a concentration of 0.1 mL/100 g of body weight for four

weeks. Mice in Group G3 were given an oral dose of Au-NPs solution at 0.1 mL/100 g of body weight daily for four weeks. Group G4 received an injection of 0.1 mL of CCl<sub>4</sub>. After 60 minutes, the mice were given an oral dose of 300 mg/kg bromelain solution at a daily dose of 0.1 mL for four weeks, and mice in Group G5 were injected with 0.1 mL of CCl<sub>4</sub>. After 60 minutes, the mice received the oral dosage of 300 mg/kg Au-NPs bromelain for four weeks.

### **Histopathology and immunohistochemistry**

The testis samples were fixed in formalin 10% for 48 hours and washed under running water. Several procedures for histological examinations were performed using the method of [Stevens and Bancroft \(2010\)](#). A MEIJI light microscope (Meiji Techno, Japan), equipped with a high-resolution digital camera (Canon), was utilized to capture images of the slides. Immunohistochemical staining for Ki-67 and Caspase-9 was conducted using immunohistochemical staining kits (DAKO, USA) in accordance with the manufacturer's instructions. Briefly, four mm-thick tissue sections were deparaffinized in xylene and hydrated through a graded ethanol series. Antigen retrieval was conducted using a high pH solution at 95°C in a water bath for 40 minutes. Endogenous peroxidase activity was inhibited by applying peroxide black and incubating for 10 minutes in a humid chamber. Subsequently, three drops of peroxide powder block were added and incubated for 10 minutes in a humid chamber. Following a 20-minute incubation with the primary antibody, the secondary antibody HRP was applied and incubated for a further 10 minutes. The slides were then counterstained with Mayer's hematoxylin for one minute, mounted with cover slides, and prepared for microscopic examination and scoring ([Ali et al., 2024](#)). Immunohistochemical changes in the testes were documented by staining intensity, which can be scored to identify changes in protein expression. These changes indicated how a substance (antigen) was distributed and its concentration within the tissue, categorized as no changes (0), mild (1), moderate (2), and severe (3). Grading was determined according to the following percentage ranges. Less than 30% changes from 0%, up to 30% changes (mild change), 30%-50% (moderate change), and more than 50% (severe change, [Korany et al., 2019](#)).

## **RESULTS**

The paraffin section of the control testis exhibited normal-sized and well-structured seminiferous tubules, with intact basement membranes and a typical thickness of the epithelial germinal layer. The lumen was filled with spermatozoa, and the interstitial tissue appeared normal (Figure 1). Group G2, injected with CCl<sub>4</sub>, displayed vacuolation within the germinal epithelium lining the seminiferous tubules, along with mild cellular swelling of spermatogonia cells, and some figures of necrosis and vascular congestion were observed within the interstitial tissue (Figure 2). Additionally, Group G3 (animals injected with gold nanoparticles) exhibited marked hypertrophy of seminiferous tubules with normal testicular interstitium (Figure 3). The testis sample in the group treated with bromelain solution demonstrated hyperplasia of germinal epithelium (Figure 4). Group G5 treated with Au-NPs-Bromelain illustrated almost normal architecture with marked hypertrophy of seminiferous tubules associated with normal interstitial cells (Figure 5).

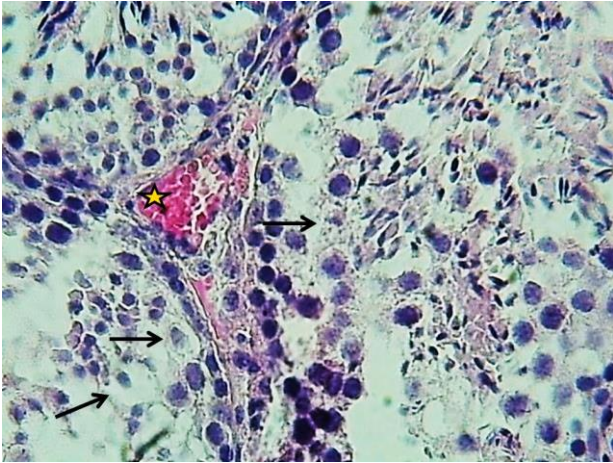
### **Immunohistochemical findings**

#### ***Ki-67 immunohistochemical results***

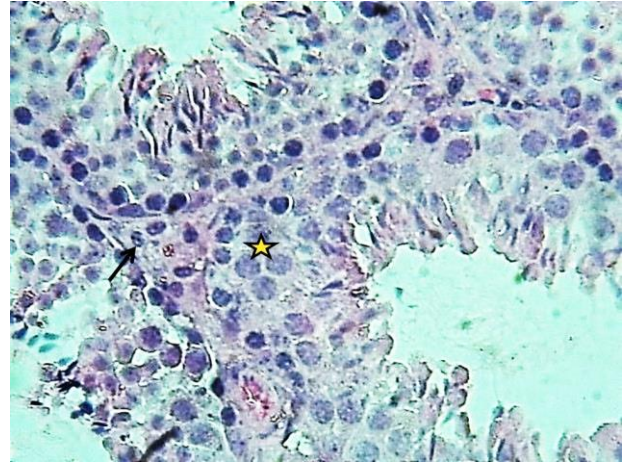
The immunodetection of the proliferation marker Ki-67 in the testis demonstrated intense (+3) staining, indicative of active spermatogenesis. However, a moderate level of Ki-67 staining (+2) was observed in the basal epithelium of seminiferous tubules in Group G2 treatment with CCl<sub>4</sub>. The expression of Ki-67 remained largely unchanged following exposure to AuNPs, with many cells continuing to exhibit strong Ki-67 staining, scored as +3. Group G4 had a weak score of +1. Ki-67 expression increased in the testicular germinal epithelium treated with AuNPs-Brom solution with a +2 score (Figure 6).

#### ***Caspase-9 immunohistochemical results***

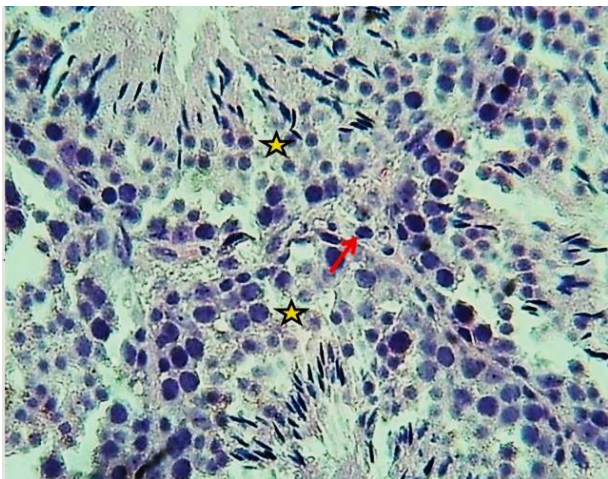
Immunohistochemical staining of caspase-9 in mice testes exhibited moderate positive staining results (+2) in the control group (G1), Group G3, and Group G5. In contrast, intense staining results (+3) were observed in Group G2 and Group G4 (Figure 7).



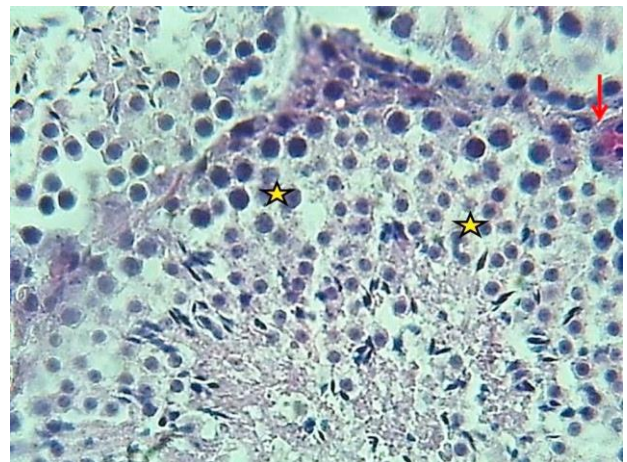
**Figure 1.** The testis section in male albino mice aged 8-10 weeks received normal saline. The control group with normal appearance of germinal epithelial cells (Asterisk) with normal testicular interstitial cells (Black arrow). H&E staining, 400x.



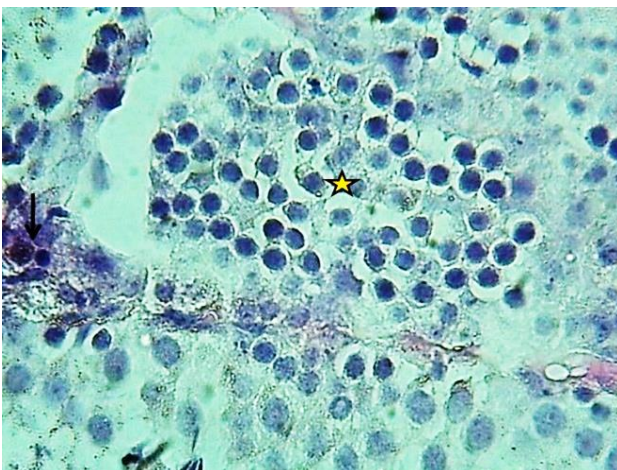
**Figure 2.** Testis section in male albino mice aged 8-10 weeks treated with Carbon tetrachloride. Group G2 with Mild cellular swelling of spermatogium cells with some figures of necrosis (Arrows) and vascular congestion of interstitial tissue (Asterisk). H&E staining, 400x.



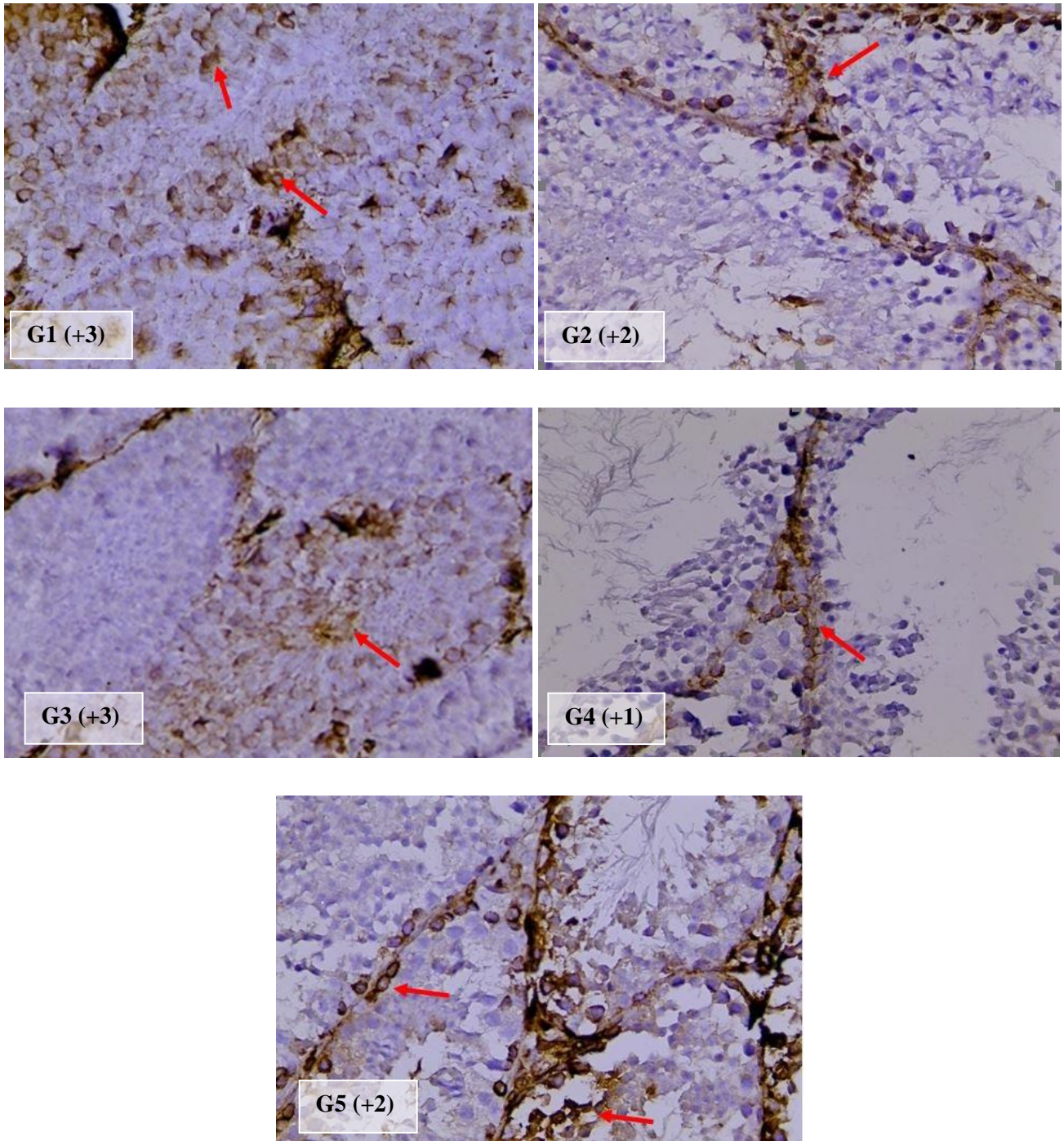
**Figure 3.** Testis section in male albino mice aged 8-10 weeks treated with gold nanoparticle solution for four weeks. Group G3 with normal appearance of germinal epithelial cells (Asterisks) with normal testicular interstitial cell (Arrow). H&E staining, 400x.



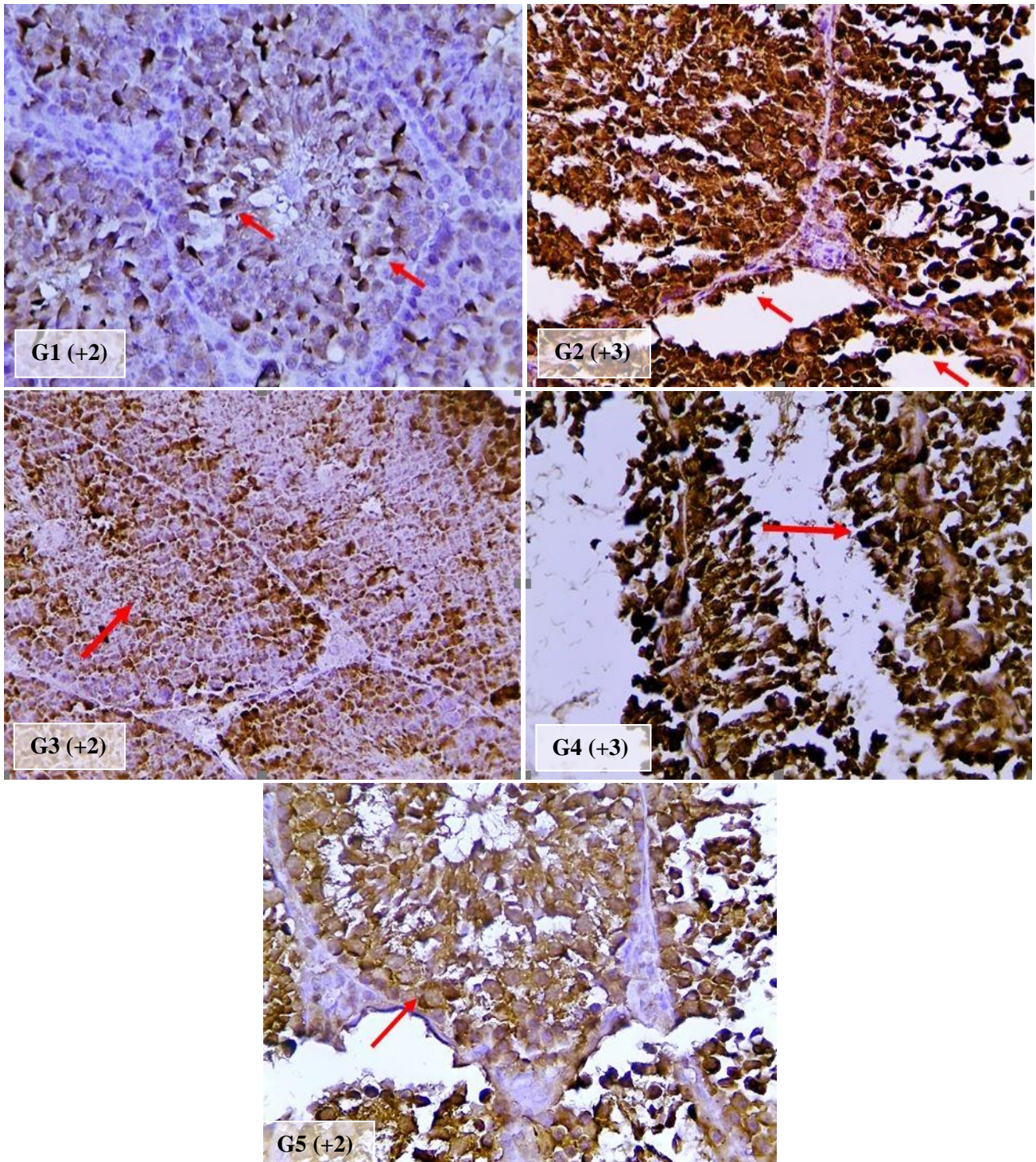
**Figure 4.** Testis section in male albino mice aged 8-10 weeks treated with Carbon tetrachloride. In group G4, after 60 minutes, the mice were given an oral dose of 300 mg/kg bromelain solution, marked hyperplasia of germinal epithelium (Asterisks) with congestion of interstitial blood vessels (Arrow). H&E staining, 400x.



**Figure 5.** Testis section in adult mice treated with Carbon tetrachloride with marked hyperplasia of germinal epithelium (Asterisks). After 60 minutes, the mice received the oral dosage of 300 mg/kg gold nanoparticles bromelain for 4 weeks interstitial cells (Arrow). H&E staining, 400x.



**Figure 6.** Adult mice (*Mus musculus*) testis scoring with immunohistochemistry staining. The control group (**G1**) illustrates a strongly positive expression of Ki-67 (+3, Red arrow), **G2** shows a slight positive expression of Ki-67 (+2, Red arrow), **G3** exhibits a severe positive expression of Ki-67 (+3, Red arrow), **G4** shows a weak positive expression of Ki-67 (+1, Red arrow), and **G5** exhibits a moderate positive expression of Ki-67 (+2, Red arrow, IHC, 40X).



**Figure 7.** Adult mouse testis (*Mus musculus*) with immunohistochemistry staining. Control group (G1) shows a slight positive expression of expression of caspase-9 (+2, Red arrow), G2 illustrates a strongly positive expression of caspase-9 (+3 Red arrow), G3 exhibits a moderate positive expression caspase-9 (+2, Red arrow), G4 shows a severe positive expression caspase-9 (+3 Red arrow), and G5 illustrates a moderate positive expression of caspase-9 (+2, Red arrow, IHC, 40X).

## DISCUSSION

Histological examination revealed abnormalities in the testicular structure of the CCl<sub>4</sub> group. Mice treated with gold nanoparticles had no substantial protective effect, whereas animals treated with bromelain exhibited slight improvements in histological structure. Meanwhile, animals treated with bromelain loaded with gold nanoparticles demonstrated a more protective effect on testicular tissue, exhibiting regular seminiferous tubules, a normal interstitial space, occasional hemorrhages, and a germinal epithelium containing cells in the spermatogenesis stage that were similar to those in the control. According to the current results, CCl<sub>4</sub> injection caused slight hyperplasia in the germinal epithelial cells and

congestion in the interstitial tissue. These findings are in agreement with a study of [Gülhan et al. \(2023\)](#), who demonstrated that CCl<sub>4</sub> caused seminiferous tubule atrophy, degeneration, basal membrane separation, and an increase in interstitial space in rat testes. Another study reported that CCl<sub>4</sub> reduced the number of spermatogonia, primordial spermatocytes, Sertoli cells, and interstitial cells ([Eljaafari et al., 2024](#)). The alterations in testicular histology during the present study indicated the toxic effects of CCl<sub>4</sub>. The CCl<sub>4</sub> itself is not toxic but is metabolized by cytochrome P450 enzymes in the body into the free radical CCl<sub>3</sub> and other metabolites ([Cohen et al., 2023](#)). Since CCl<sub>4</sub> rapidly diffuses through tissues after absorption, especially tissues rich in lipids ([Abu et al., 2022](#)), it may negatively affect the testes, which contain high amounts of polyunsaturated fatty acids ([Tran et al., 2017](#)). [Hashem \(2021\)](#) found that free radicals produced by CCl<sub>4</sub> may directly induce male infertility or indirectly cause reproductive failure by disrupting male hormone balance ([Dutta et al., 2021](#)). Another study conducted by [Azouz et al. \(2023\)](#) indicated that the testis is naturally vulnerable to oxidative stress due to its high content of unsaturated fatty acids, which are prone to damage and produce reactive oxygen species (ROS). Elevated ROS levels can impair testicular function and cause oxidative damage. The conjugation of bromelain with gold nanoparticles protected testicular tissue against CCl<sub>4</sub> toxicity by integrating bromelain's antioxidant and anti-inflammatory properties with the unique conductivity of gold nanoparticles. This combination functioned synergistically to enhance cellular function by modulating ROS levels and restoring normal tissue structure ([Abeed and Al-Shmgani, 2024](#); [Hosseinpour et al., 2025](#)). Additionally, bromelain can enhance the production of inflammatory mediators such as interleukin (IL)-1 $\beta$ , IL-6, interferon (IFN)- $\gamma$ , and tumor necrosis factor (TNF)- $\alpha$  by immune cells, including mouse macrophages ([Rathnavelu et al., 2016](#)). Studies on the toxicological impact of AuNPs on male reproductive health have indicated contradictory results. A study of [Li et al. \(2012\)](#) found that intravenous or intraperitoneal injection of AuNPs did not affect sperm quality, spermatogenesis, or fertility. Conversely, another study suggested that AuNPs might reduce the ability of sperm to fertilize *in vitro* ([Das et al., 2016](#)). The current study found that AuNPs did not affect testicular structure. Animals treated only with bromelain showed minor improvements in testicular histology, whereas those treated with a conjugate of bromelain and gold nanoparticles exhibited a more notable protective effect against CCl<sub>4</sub> toxicity.

The Ki-67 protein is a DNA-binding protein that is strongly associated with cellular proliferation. Its expression correlates with the rate of proliferation. It is expressed during all active phases of the cell cycle but is absent in resting cells. Therefore, levels of Ki-67 protein expression in the testis are conventionally utilized as a marker of spermatogenic cell proliferation and can be employed to evaluate the status of spermatogenesis ([Zhao et al., 2018](#)). In the current study, Ki-67 immunostaining revealed the expected pattern of cellular proliferation in the testes of the control group, but was remarkably decreased in the CCl<sub>4</sub> group. It is well known that CCl<sub>4</sub>'s harmful effects are the result of excessive ROS generation ([Eljaafari et al., 2024](#)). Increased ROS formation, resulting from both internal and external stimuli, can lead to oxidative stress, which alters the structure and function of phospholipids and proteins. The ROS attack DNA in the nucleus, fragmenting it and triggering apoptosis, which consequently alters gene and protein expression. Additionally, endogenous ROS can function as second messengers in regulating cell signaling pathways and transmitting signals crucial for controlling spermatogonia self-renewal and proliferation, which suggests a potential impact of ROS on the nuclear proliferation protein Ki-67 ([Juárez-Rojas et al., 2022](#)). The AuNPs solution did not cause notable changes in Ki-67 expression, while Ki-67 levels were lower in the group treated only with bromelain. This may be due to hypoplasia and degeneration of the germinal epithelium caused by CCl<sub>4</sub>. Regarding the conjugation of bromelain and AuNPs, immunohistochemistry results indicated an increase in Ki-67 expression. This increase may be attributed to bromelain's protective properties and nanoparticles' tremendous advantages for absorbing medications ([Chakraborty et al., 2021](#)). Previous results have demonstrated that bromelain reduces the adverse effects of oxidative stress on the male reproductive system by increasing sperm count, normalizing sperm morphology, and elevating testosterone levels ([Khazaeel et al., 2022](#)), which may also influence Ki-67 expression. The immunohistochemistry analysis in the present study revealed different levels of positive caspase-9 expression in mouse testis tissue sections, with a score of +2 for the control group and scores ranging from +2 to +3 for the different treatment groups. Apoptosis, or programmed cell death, is an essential mechanism in the normal growth and function of the mouse testis, as it regulates the number of germ cells during spermatogenesis. During spermatogenesis, a significant number of germ cells undergo apoptosis. Several variables influence spermatogenesis, including hormonal balance, developmental stage, and specific stages within the spermatogenic cycle ([Dunkel et al., 1997](#)). Testis tissue sections in the group treated with CCl<sub>4</sub> indicated increased Caspase-9 immunorexpression, reaching a score of +3. The CCl<sub>4</sub> metabolization produces ROS, which can cause apoptosis, autophagy, inflammation, and other pathogenic phenomena, and the mitochondrial pathway plays a significant role in CCl<sub>4</sub>-induced apoptosis ([Zhou et al., 2022](#)). The ROS disrupts mitochondrial membrane potential and alters the interactions of pro- and anti-apoptotic proteins, leading to germ cell death ([El-Wakf et al., 2020](#)). In response to mitochondrial stress, cytochrome C is generated, which activates caspases-3 and -9, leading to apoptosis ([Wang, 2015](#)) and potentially affecting the immunohistochemical expression of caspase-9. The current study indicated that there were

no considerable differences in the expression of caspase-9 in mice that received an oral dose of Au-NP solution, compared to the control group. Several studies have investigated the correlation between bromelain and apoptosis; however, the results have been inconsistent. Scientists have demonstrated that bromelain induces apoptosis by activating caspase-dependent apoptotic pathways in cancer cells (Chang *et al.*, 2019). The present study demonstrated that bromelain decreased caspase-9 expression by lowering its score, which was in accordance with the findings of Rathnavelu *et al.* (2016), who reported that bromelain reduced apoptosis and protected cells from damage. One potential explanation is that bromelain enhances the production of pro-apoptotic proteins, leading to the release of cytochrome C from the mitochondria and the activation of the mitochondrial apoptosis pathway (Rathnavelu *et al.*, 2016). Alternatively, it inhibits the generation of inflammatory cytokines, which can lead to cell death and an inflammatory environment (Bahar *et al.*, 2024). In a study, bromelain has been identified to activate caspases in some cases, but it may downregulate or inhibit caspase-9 in other situations (Bhui *et al.*, 2009).

## CONCLUSION

The current results suggested that conjugating bromelain with gold nanoparticles at a dosage of 300 mg/kg may effectively reduce CCl<sub>4</sub> toxicity by repairing the natural antioxidant defense system, enhancing protein function, increasing cell proliferation, and preventing programmed cell death, as well as improving histological structure following pathological exposure. The efficacy of Au-NPs-Bromelain was more effective in the repair of testicular damage than the single administration of bromelain. Further studies are needed to fully understand the interaction between bromelain and caspase-9 in different cell types.

## DECLARATIONS

### Funding

The present study has not been supported financially.

### Availability of data and materials

The data that support the findings of this study are available from the corresponding author upon reasonable request.

### Acknowledgments

The authors wish to express their gratitude to the Department of Biology, College of Education for Pure Sciences/Ibn Al-Haitham, University of Baghdad, as well as to the staff of the Biotechnology Research Center at Al Nahrain University for providing facilities and their assistance throughout the present study.

### Authors' contributions

Saddama Saed Faraj and Rana Hanan Khudhair Al-Rubaye conceived and planned the experiments. Baydaa Hussain Mutlak conducted the preparation of gold nanoparticles and the immunohistochemical study. Entidhar Mohammed Mnati reviewed and documented the histological results. All authors participated in the experiments and contributed to the interpretation of the results. Baydaa Hussain Mutlak assumed the lead in the manuscript preparation. All authors provided critical feedback, read, and approved the final edition of the manuscript.

### Competing interests

The authors declared no conflict of interest concerning the publication of this manuscript.

### Ethical considerations

All authors contributed to the preparation of this original paper. This article was originally written by the authors and has not been published elsewhere. All authors checked the text of the article and confirmed that the article is written based on their original scientific results and they never used the AI tools during this study.

## REFERENCES

- Abeed BS and Al-Shmgani HA (2024). Evaluation of the potential protective role of Galangin associated with gold nanoparticles in the histological and functional structure of testis of adult male albino mice administered with carbon tetrachloride. *Baghdad Science Journal*, 21(8): 17. DOI: <https://www.doi.org/10.21123/bsj.2024.9086>
- Abeed BS, Al-Shmgani HS, Khalil KA, and Mohammed HA (2023). Histological and biochemical effects of Galangin conjugated gold nanoparticles

- on the kidneys damage induced by carbon tetrachloride of adult male Albino mice. *Ibn AL-Haitham Journal for Pure and Applied Sciences*, 36(3): 72-84. Available at: <https://jih.uobaghdad.edu.iq/index.php/j/article/view/3250>
- Abu OD, Iyare HE, and Ogboi KU (2022). Cardiac oxidative status in CCl<sub>4</sub>-exposed rats treated with extracts of *Dialium guineense* stem bark. *Global Journal of Scientific Frontier Research*, 22(B1): 37-42. Available at: <https://journalofscience.org/index.php/GJSFR/article/view/102574>
- Ali HI, Mutlak BH, Alshareef SA, and Alhuwaymil Z (2024). Effect of CCl<sub>4</sub> on renal tissues of male mice and prevented by pretreatment with bromelain loaded with gold nanoparticles: Histopathological and Caspase-9 expression alterations. *Trends in Sciences*, 21(12): 8358. DOI: <https://www.doi.org/10.48048/tis.2024.8358>
- Asadi A, Ghahremani R, Abdolmaleki A, and Rajaei F (2021). Role of sperm apoptosis and oxidative stress in male infertility: A narrative review. *International Journal of Reproductive Biomedicine*, 19(6): 493-504. DOI: <https://www.doi.org/10.18502/ijrm.v19i6.9371>
- Azouz RA, Korany RM, and Noshay PA (2023). Silica nanoparticle-induced reproductive toxicity in male albino rats via testicular apoptosis and oxidative stress. *Biological Trace Element Research*, 201(4): 1816-1824. DOI: <https://www.doi.org/10.1007/s12011-022-03280-w>
- Bahar R, Chegeni MJ, Tahvildari A, Sani M, Khakpour Y, Hashemabady M, Sagharichi M, Balaghirad N, Taghizadeh M, Mehranpour M et al. (2024). Bromelain decreases oxidative stress and Neuroinflammation and improves motor function in adult male rats with cerebellar Ataxia induced by 3-acetylpyridine. *Neuropeptides*, 107: 102455. DOI: <https://www.doi.org/10.1016/j.npep.2024.102455>
- Bhui K, Prasad S, George J, and Shukla Y (2009). Bromelain inhibits COX-2 expression by blocking the activation of MAPK regulated NF-kappa B against skin tumor-initiation triggering mitochondrial death pathway. *Cancer Letters*, 282(2): 167-176. <https://www.doi.org/10.1016/j.canlet.2009.03.003>
- Brito AMM, Oliveira V, Icimoto MY, and Nantes-Cardoso IL (2021). Collagenase activity of bromelain immobilized at gold nanoparticle interfaces for therapeutic applications. *Pharmaceutics*, 13(8): 1143. DOI: <https://www.doi.org/10.3390/pharmaceutics13081143>
- Chakraborty AJ, Mitra S, Tallei TE, Tareq AM, Nainu F, Cicia D, Dhama K, Emran TB, Simal-Gandara J, and Capasso R (2021). Bromelain a potential bioactive compound: A comprehensive overview from a pharmacological perspective. *Life*, 11(4): 317. DOI: <https://www.doi.org/10.3390/life11040317>
- Chang TC, Wei PL, Makondi PT, Chen WT, Huang CY, and Chang YJ (2019). Bromelain inhibits the ability of colorectal cancer cells to proliferate via activation of ROS production and autophagy. *PloS One*, 14(1): e0210274-e0210292. DOI: <https://www.doi.org/10.1371/journal.pone.0210274>
- Cohen SM, Bevan C, Gollapudi B, and Klaunig JE (2023). Evaluation of the carcinogenicity of carbon tetrachloride. *Journal of Toxicology and Environmental Health, Part B*, 26(6): 342-370. DOI: <https://www.doi.org/10.1080/10937404.2023.2220147>
- Das J, Choi YJ, Song H, and Kim JH (2016). Potential toxicity of engineered nanoparticles in mammalian germ cells and developing embryos: Treatment strategies and anticipated applications of nanoparticles in gene delivery. *Human Reproduction Update*, 22(5): 588-619. DOI: <https://www.doi.org/10.1093/humupd/dmw020>
- Dunkel L, Hirvonen V, and Erkkilä K (1997). Clinical aspects of male germ cell apoptosis during testis development and spermatogenesis. *Cell Death & Differentiation*, 4(3): 171-179. Available at: <https://www.nature.com/articles/4400234>
- Dutta S, Sengupta P, Slama P, and Roychoudhury S (2021). Oxidative stress, testicular inflammatory pathways, and male reproduction. *International Journal of Molecular Sciences*, 22(18): 10043. DOI: <https://www.doi.org/10.3390/ijms221810043>
- Eljaafari H, Mabrouk ZE, Mohamed F, Tounsi H, and Sasi SM (2024). Carbon tetrachloride-induced testicular toxicity and histopathological alteration in male Swiss Albino mice. *AlQalam Journal of Medical and Applied Sciences*, 7(1): 36-43. Available at: <https://journal.utripoli.edu.ly/index.php/Alqalam/article/view/450>
- El-Wakf AM, El-Habibi ESM, Ali DA, Abd El-Ghany E, and Elmougy R (2020). Marjoram and sage oils protect against testicular apoptosis, suppressed Ki-67 expression and cell cycle arrest as a therapy for male infertility in the obese rats. *Journal of Food Biochemistry*, 44(1): e13080. DOI: <https://www.doi.org/10.1111/jfbc.13080>
- Gülhan B, Taşlıdere E, Vardi N, TAŞLİDERE A, and Elbe H (2023). Protective effects of caffeic acid phenethyl ester against carbon tetrachloride-induced testicular damage in rats: A histological study. *Namik Kemal Medical Journal*, 11(1): 17-21. DOI: <https://www.doi.org/10.4274/nkmj.galenos.2023.82474>
- Hashem AS (2021). Defensive impact of propolis against CCl<sub>4</sub> actuated rats' testicular damage. *Journal of Advanced Veterinary and Animal Research*, 8(1): 70-77. DOI: <http://www.doi.org/10.5455/javar.2021.h487>
- Hosseinpour M, Dalband AM, Lajevardi Z, SoltanattarA, Tafazolimoghdam A, Karamian A, Abdollahifar MA, Abbaszadeh HA, Hodaiepour M, Charmchi A et al. (2025). The protective effect of bromelain on testicular dysfunction and oxidative stress induced by REM sleep deprivation in adult male rats. *Tissue and Cell*, 95: 102927. DOI: <https://www.doi.org/10.1016/j.tice.2025.102927>
- Juárez-Rojas L, Casillas F, López A, Betancourt M, Ommati MM, and Retana-Márquez S (2022). Physiological role of reactive oxygen species in testis and epididymal spermatozoa. *Andrologia*, 54(4): e14367. DOI: <https://www.doi.org/10.1111/and.14367>
- Kansakar U, Trimarco V, Manzi M V, Cervi E, Mone P, and Santulli G (2024). Exploring the therapeutic potential of bromelain: Applications, benefits, and mechanisms. *Nutrients*, 16(13): 2060-2079. DOI: <https://www.doi.org/10.3390/nu16132060>
- Khazaeel K, Rad OR, Jamshidian J, Tabandeh MR, Mohammadi G, and Atashfaraz A (2022). Effect of bromelain on sperm quality, testicular oxidative stress and expression of oestrogen receptors in BISPHENOL-A treated male mice. *Andrologia*, 54(11): e14584. DOI: <https://www.doi.org/10.1111/and.14584>
- Korany RM, Ahmed KS, Halawany HA, and Ahmed KA (2019). Effect of long-term arsenic exposure on female Albino rats with special reference to the protective role of *Spirulina platensis*. *Exploratory Animal and Medical Research*, 9(2): 125-136. Available at: <https://doaj.org/article/4cde25e3d25d44bda753cb0365949e5d>
- Li WQ, Wang F, Liu ZM, Wang YC, Wang J, and Sun F (2012). Gold nanoparticles elevate plasma testosterone levels in male mice without affecting fertility. *Small*, 9(9-10): 1708-1714. DOI: <https://www.doi.org/10.1002/smll.201201079>
- Menon SS, Guruvayoorappan C, Sakthivel KM, and Rasmi RR (2019). Ki-67 protein as a tumour proliferation marker. *Clinica Chimica Acta*, 491: 39-45. DOI: <https://www.doi.org/10.1016/j.cca.2019.01.011>
- Rahmouni F, Daoud S, and Rebai T (2019). Teucrium polium attenuates carbon tetrachloride-induced toxicity in the male reproductive system of rats. *Andrologia*, 51(2): e13182. DOI: <https://www.doi.org/10.1111/and.13182>
- Rajkumar M, Davis Presley SI, Thiyagarajulu N, Girigoswami K, Janani G, Kamaraj C, Madheswaran B, Prajapati B, Ali N, and Rashid Khan M (2025). Gelatin/PLA-loaded gold nanocomposites synthesis using *Syzygium cumini* fruit extract and their antioxidant, antibacterial, anti-inflammatory, antidiabetic and anti-Alzheimer's activities. *Scientific Reports*, 15(1): 2110. DOI: <https://www.doi.org/10.1038/s41598-024-84098-5>

- Rathnavelu V, Alitheen NB, Sohila S, Kanagesan S, and Ramesh R (2016). Potential role of bromelain in clinical and therapeutic applications. *Biomedical Reports*, 5(3): 283-288. DOI: <https://www.doi.org/10.3892/br.2016.720>
- Rohmah A, Prabowo H A, Setiasih S, Handayani S, Jufri M, and Hudiyono S (2021). The evaluation of activity and stability of isolated bromelain from pineapple cores (*Ananas comosus* [L.] Merr) and *in vitro* penetration test of nanoemulsion topical base. *International Journal of Applied Pharmaceutics*, 13(5): 336-342. DOI: <https://www.doi.org/10.22159/ijap.2021v13i5.41769>
- Sherry D, McCulloch A, Liang Q, Reimann S, and Newman PA (2018). Current sources of carbon tetrachloride (CCl<sub>4</sub>) in our atmosphere. *Environmental Research Letters*, 13(2): 024004. DOI: <https://www.doi.org/10.1088/1748-9326/aa9c87>
- Sönmez M, Türk G, Çeribaşı S, Çiftçi M, Yüce A, Güvenç M, Özer Kaya S, Çayand M, and Aksakal M (2014). Quercetin attenuates carbon tetrachloride-induced testicular damage in rats. *Andrologia*, 46(8): 848-858. DOI: <https://www.doi.org/10.1111/and.12159>
- Stevens A and Bancroft JD (2010). Theory and practice of histological techniques. Churchill Livingstone., London, pp. 174-176. Available at: [https://www.google.iq/books/edition/Theory\\_and\\_Practice\\_of\\_Histological\\_Tech/Dhn2KispfdQC?hl=ar&gbpv=1&dq=Theory+and+Practice+of+Histological+Techniques&printsec=frontcover](https://www.google.iq/books/edition/Theory_and_Practice_of_Histological_Tech/Dhn2KispfdQC?hl=ar&gbpv=1&dq=Theory+and+Practice+of+Histological+Techniques&printsec=frontcover)
- Tran LV, Malla BA, Kumar S, and Tyagi AK (2017). Polyunsaturated fatty acids in male ruminant reproduction-a review. *Asian-Australasian Journal of Animal Sciences*, 30(5): 622-637. DOI: <https://www.doi.org/10.5713/ajas.15.1034>
- Unsal V, Cicek M, and Sabancilar İ (2021). Toxicity of carbon tetrachloride, free radicals and role of antioxidants *Reviews on Environmental Health*, 36(2): 279-295. DOI: <https://www.doi.org/10.1515/reveh-2020-0048>
- Varilla C, Marcone M, Paiva L, and Baptista J (2021). Bromelain, a group of pineapple proteolytic complex enzymes (*Ananas comosus*) and their possible therapeutic and clinical effects. A summary. *Foods*, 10(10): 2249. DOI: <https://www.doi.org/10.3390/foods10102249>
- Wang K (2015). Autophagy and apoptosis in liver injury. *Cell Cycle*, 14(11): 1631-1642. DOI: <https://www.doi.org/10.1080/15384101.2015.1038685>
- Yakut S, Karabulut M, Koca RH, Erbaş E, Özkanlar S, Gençer BT, Kara A, and Kumar KSJ (2025). Protective effects of bromelain in testicular torsion-detorsion: Reducing inflammation, oxidative stress, and apoptosis while enhancing sperm quality. *Biomolecules*, 15(2): 292. DOI: <https://www.doi.org/10.3390/biom15020292>
- Yu W, Zhu H, Huang R, Yan B, Xu B, Shi Y, Mao J, Liu Z, and Wang J (2024). Roles of cyt-c/caspase-9/caspase-3/bax/bcl-2 pathway in cd-induced testicular injury in rats and the protective effect of quercetin. *Toxicol*, 237(3): 107561. DOI: <https://www.doi.org/10.1016/j.toxicol.2023.107561>
- Zhao WP, Wang HW, Liu J, Tan PP, Luo XL, Zhu SQ, Chen XL, and Zhou BH (2018). Positive PCNA and Ki-67 expression in the testis correlates with spermatogenesis dysfunction in fluoride-treated rats. *Biological Trace Element Research*, 186(1): 489-497. DOI: <https://www.doi.org/10.1007/s12011-018-1338-6>
- Zhou C, Liu A, Liu G, Yang C, Zhou Q, Li H, Yang H, Yang M, Li G, Si H et al. (2022). Protective effects of *Sophorae tonkinensis* Gagnep. (Fabaceae) Radix et Rhizoma water extract on carbon tetrachloride-induced acute liver injury. *Molecules*, 27(24): 8650. DOI: <https://www.doi.org/10.3390/molecules27248650>

**Publisher's note:** Sciencline Publication Ltd. remains neutral with regard to jurisdictional claims in published maps and institutional affiliations.



**Open Access:** This article is licensed under a Creative Commons Attribution 4.0 International License, which permits use, sharing, adaptation, distribution and reproduction in any medium or format, as long as you give appropriate credit to the original author(s) and the source, provide a link to the Creative Commons licence, and indicate if changes were made. The images or other third party material in this article are included in the article's Creative Commons licence, unless indicated otherwise in a credit line to the material. If material is not included in the article's Creative Commons licence and your intended use is not permitted by statutory regulation or exceeds the permitted use, you will need to obtain permission directly from the copyright holder. To view a copy of this licence, visit <https://creativecommons.org/licenses/by/4.0/>.

© The Author(s) 2025